

*A*RCHAEOLOGICAL RECOVERY  
ON BEHALF OF THE  
U.S. ARMY CORPS OF ENGINEERS  
WEST POINT, NEW YORK

*PREPARED FOR*

U.S. ARMY CORPS OF ENGINEERS,  
ST. LOUIS DISTRICT  
ST. LOUIS, MISSOURI

*PREPARED BY*

COMMONWEALTH HERITAGE  
GROUP, INC.

ALEXANDRIA, VIRGINIA



SEPTEMBER 2017



**ARCHAEOLOGICAL RECOVERY ON BEHALF OF THE U.S.  
ARMY CORPS OF ENGINEERS**

**WEST POINT, NEW YORK**

Prepared for

U.S. ARMY CORPS OF ENGINEERS, ST. LOUIS DISTRICT  
1222 Spruce Street  
St. Louis, MO 63103-2833

By

Joseph F. Balicki, RPA  
and  
W. Brett Arnold, RPA

FINAL REPORT

COMMONWEALTH HERITAGE GROUP, INC.  
5250 Cherokee Avenue, Suite 300  
Alexandria, Virginia 22312

MAY 2017





## MANAGEMENT SUMMARY

The Mandatory Center of Expertise for the Curation and Management of Archaeological Collections (MCX CMAC) was asked to support the emergency forensic archaeological recovery/disinterment of an individual buried in the West Point Post Cemetery. The cemetery is located at 329 Washington Rd, West Point, New York 10996. The burial is Grave 01, located at the West Point Post Cemetery, West Point, Orange County, New York, in Section 11, Row A.

The purpose of this investigation was for Sky Communications-Commonwealth Heritage Group Joint Venture (SKY-CHG JV), contracted through the United States Army Corps of Engineers St. Louis District MCX CMAC, to conduct an emergency forensic archaeological recovery excavation of human remains and associated funerary objects partially exposed during construction activities. SKY-CHG JV is a Joint Venture partnership between the Commonwealth Heritage Group and Skynet, Inc. an 8a company operated by members of Acoma Pueblo. SKY-CHG JV also managed the post-excavation skeletal analysis undertaken by a board certified forensic anthropologist (certified through the American Board of Forensic Anthropology®) and subsequent DNA analysis. Staff from Commonwealth Heritage Group, Inc. (CHG) conducted the investigation for SKY-CHG JV.

On 21 October 2016, contractors excavating to install a retaining wall at the Molly Corbin Enhancement Project disturbed a grave (Section 11, Row A, Grave 01) located directly in front of the Margaret Corbin Monument. The construction company ceased excavation activity and contacted West Point Cultural Resources staff and the West Point Military Police. The police informed West Point Criminal Investigation Division (CID) agents, who contacted the office of the Orange County Coroner. CID is responsible for confirming that the remains are human and making the legal determination that they either constitute a crime scene or are archaeological or historic in nature.

From 24 to 26 October 2016, CID and West Point Cultural Resources staff removed all remains and associated artifacts exposed by excavation machinery. CID took possession of the recovered skeletal remains and associated artifacts.

The emergency recovery by MCX CMAC and CHG staff was undertaken between 29 November and 3 December 2016. The recovery included exposing the burial's undisturbed remnants, recovering the remaining skeletal material, and recording the burial.

CID transferred all skeletal material to the forensic anthropologist, who conducted an analysis of both the remains in CID custody and the remains originally removed by SKY-CHG JV.

Sex identification is based on well-established statistical procedures and extremely reliable attributes on particular bones. Post excavation analysis of the skeletal material indicates that the individual interred in the grave is a male. This conclusion is based on cranial morphology, an

analysis of the long bones' muscle attachments, fragmentary elements of the innominate, and DNA analysis.

Three elements from the excavated remains were given to the Merriweather Ancient DNA and Forensic Laboratory at Binghamton University to confirm the individual's sex. These elements consisted of one tooth, one femur, and one phalange. Three clean samples were extracted and tested using amelogenin primers, which can detect a 6 pb deletion that indicates whether the amelogenin gene comes from an X or Y chromosome. The amelogenin sequence from the samples showed the presence of a Y chromosome, proving that the sample comes from a biological male. A partial sequence of the individual's mitochondrial DNA belonged to haplogroup M, C, or N, indicating that the individual is of European or Asian descent.

## ACKNOWLEDGMENTS

The emergency recovery of the remains from the disturbed Margaret Corbin grave site was successfully accomplished in a short timeframe, requiring a number of people from different organizations to come together in the effort to successfully plan, coordinate, and conduct the investigations. Commonwealth Heritage Group, Inc. appreciates the contributions of the following individuals, who provided significant support and information on this project.

Staff from the Army National Military Cemeteries (ANMC) office at Arlington National Cemetery provided logistical support at the grave site. They secured the site each day, assisted with excavation decisions, and monitored the work. ANMC staff involved in the project included LTC Lucinda Wilson, Mr. Tommy Mullen, LTC Polaris Luu, and Mr. Art Smith.

The project was sponsored by the Mandatory Center of Expertise for Curation and Management of Archaeological Collections (MCX CMAC) USACE, St. Louis District. MCX CMAC staff provided crucial pre-fieldwork logistics, developed the recovery plan, and assisted in the fieldwork.

Michael K. "Sonny" Trimble, Ph.D., RPA, Director of MCX CMAC, oversaw the project for the Government. Dr. Trimble brought his considerable experience working on burial sites to the project and developed the burial recovery plans. Further, we appreciate his constant support for the field crew for the entire duration of the fieldwork.

Nancy J. Brighton, Senior Archaeologist, U.S. Army Corps of Engineers District, New York MCX CMAC provided crucial pre-field logistical coordination and background research, and assisted with the fieldwork. The successful completion of the project could not have been achieved without Nancy's efforts.

Jacquelyn "Jackie" Rector, Physical Anthropologist, U.S. Army Corps of Engineers District, St. Louis MCX CMAC conducted pre-field analysis of the skeletal material recovered by the West Point CID and CRM staff.

Additional MCX CMAC staff members including Jennifer Riordan, Catherine "Kate" Leese, Christopher J. Koenig, Jr., and Kirby Ames, provided support vital for the undertaking of this project.

U.S. Army Garrison, West Point archeologists Paul Hudson and Patrick M. Raley conducted the initial recovery efforts and assisted with this recovery effort.

Jennifer L. McSwain, Cemetery Director, U.S. Military Academy, West Point Cemetery supported the project by allowing the field team to store and conduct partial in-field analysis of skeletal material in her office.

Elizabeth A. DiGangi, Ph.D., Forensic Anthropologist, State University of New York, Binghamton conducted preliminary in-field analysis of skeletal material and is responsible for the analysis of the skeletal material recovered from the Margaret Corbin gravesite.

D. Andrew Merriwether, Ph.D., Associate Professor of Anthropology and Biology, Chair of Anthropology, State University of New York, Binghamton conducted DNA analysis on the skeletal remains.

West Point Criminal Investigation Division (CID) agents, and CID agent Sarah Fonville in particular, were instrumental in the initial recovery efforts

The West Point Department of Public Works assisted in the investigations by providing a backhoe and operator and several staff who assisted in the excavations and facilitated the speedy completion of the fieldwork.

**TABLE OF CONTENTS**

Management Summary ..... i

Acknowledgments..... iii

Table of Contents ..... v

List of Illustrations ..... vi

1.0 Introduction..... 1

2.0 Context..... 7

    2.1 Margaret Corbin.....7

    2.2 DAR Reinternment and Memorialization.....9

    2.3 West Point Cultural Resource Management and CID Emergency Recovery  
        Investigation. ....11

3.0 Field Methods and Procedures..... 19

    3.1 Field Methods .....19

    3.2 Laboratory and Analysis Methods .....19

4.0 Field Work ..... 21

    4.1 Profile.....21

    4.2 Burial .....22

    4.3 Forensic Analysis.....23

    4.4 DNA Analysis.....24

5.0 Summary ..... 35

6.0 References Cited ..... 37

APPENDIX I:     Artifact Catalog

APPENDIX II:    Selected Artifact Photographs

APPENDIX III:   West Point Cultural Resources Program Report

APPENDIX IV:    Forensic Anthropologist Report

APPENDIX V:     DNA Analysis

APPENDIX VI:    Qualifications of Investigators

---

## LIST OF ILLUSTRATIONS

Figure 1. Project area showing original discovery area and in situ burial recovery (adopted from Hudson 2016).....	3
Figure 2. Ground surface at the Margaret Corbin Monument (right), showing limits of mechanical excavation at time of burial recovery (courtesy of U.S. Army Corps of Engineers) .....	5
Figure 3. Overview of project area showing location of burial, facing southwest .....	5
Figure 4. Daughters of the American Revolution disinterment effort (Parker 1926).....	13
Figure 5. Disinterred remains being placed in hearse (Parker 1926).....	13
Figure 6. Sketch of inadvertent discovery, showing the distribution of artifacts and remains (Hudson 2016) .....	15
Figure 7. Profile exposed by construction contractor, disturbed grave is at base of the profile .....	17
Figure 8. Overview of the project area during recovery, facing east.....	25
Figure 9. Plan view of burial.....	27
Figure 10. View of casket after skeletal material removed. Profile shows indistinct grave shaft and fill, facing north.....	29
Figure 11. Unexcavated burial showing casket hardware, facing north .....	29
Figure 12. Excavation in progress .....	31
Figure 13. Excavation of skeletal material .....	31
Figure 14. Exposed burial showing casket remnants after excavation, facing north.....	33
Figure 15. Casket hardware: lug and rail .....	33

## 1.0 INTRODUCTION

On 21 October 2016, contractors excavating to install a retaining wall for the Molly Corbin Enhancement Project disturbed a human burial (Section 11, Row A, Grave 01) located directly in front of the Margaret Corbin Monument. The construction company ceased excavation activity and contacted West Point Cultural Resources staff and the West Point Military Police. The police informed West Point Criminal Investigation Division (CID) agents, who contacted the office of the Orange County Coroner. Construction was temporarily suspended pending the removal of exposed human remains and associated artifacts, which was undertaken by CID and West Point Cultural Resources archaeologists. All related materials were given over to the custody of the CID and entered into evidence by CID agents, who determined the skeletal materials were historic and did not declare it an active crime scene. As the skeletal remains and artifacts were examined, it became clear that a significant portion of the disturbed burial had not been disturbed and remained in situ.

The Army National Military Cemeteries (ANMC) office at Arlington National Cemetery contacted the Mandatory Center of Expertise for Curation and Management of Archaeological Collections (MCX CMAC) USACE, St. Louis District, to assist in the recovery of the remaining portion of the burial at the Margaret Corbin Monument. In turn, the MCX CMAC contracted the emergency recovery project to Sky Communications-Commonwealth Heritage Group Joint Venture (SKY-CHG JV).

The purpose of this project was for SKY-CHG JV to conduct an emergency forensic archaeological recovery of the undisturbed remainder of the burial. The burial is located on the south side of the Margaret Corbin Monument (Figures 1-3). The survey was designed to comply with The New York Archaeological Council's *Standards for Cultural Resource Investigations and the Curation of Archaeological Collections in New York State* (1994), The New York Archaeological Council Standards Committee's *Guidance for Understanding and Applying The New York State Standards for Cultural Resource Investigations* (2000), and the Secretary of the Interior's *Standards and Guidelines for Archeology and Historic Preservation*. Joseph Balicki and W. Brett Arnold conducted the fieldwork for the burial recovery between 29 November and 3 December 2016. Joseph Balicki and W. Brett Arnold also prepared the report, with Sarah Ruch preparing the report's graphics. Joseph Balicki served as project manager. SKY-CHG JV also managed the post-excavation skeletal analysis undertaken by Elizabeth A. DiGangi, Ph.D., a forensic anthropologist certified by the American Board of Forensic Anthropology®, and subsequent DNA analysis performed by D. Andrew Merriwether, Ph.D. Staff from Commonwealth Heritage Group, Inc. (CHG) conducted the investigation for SKY-CHG JV.





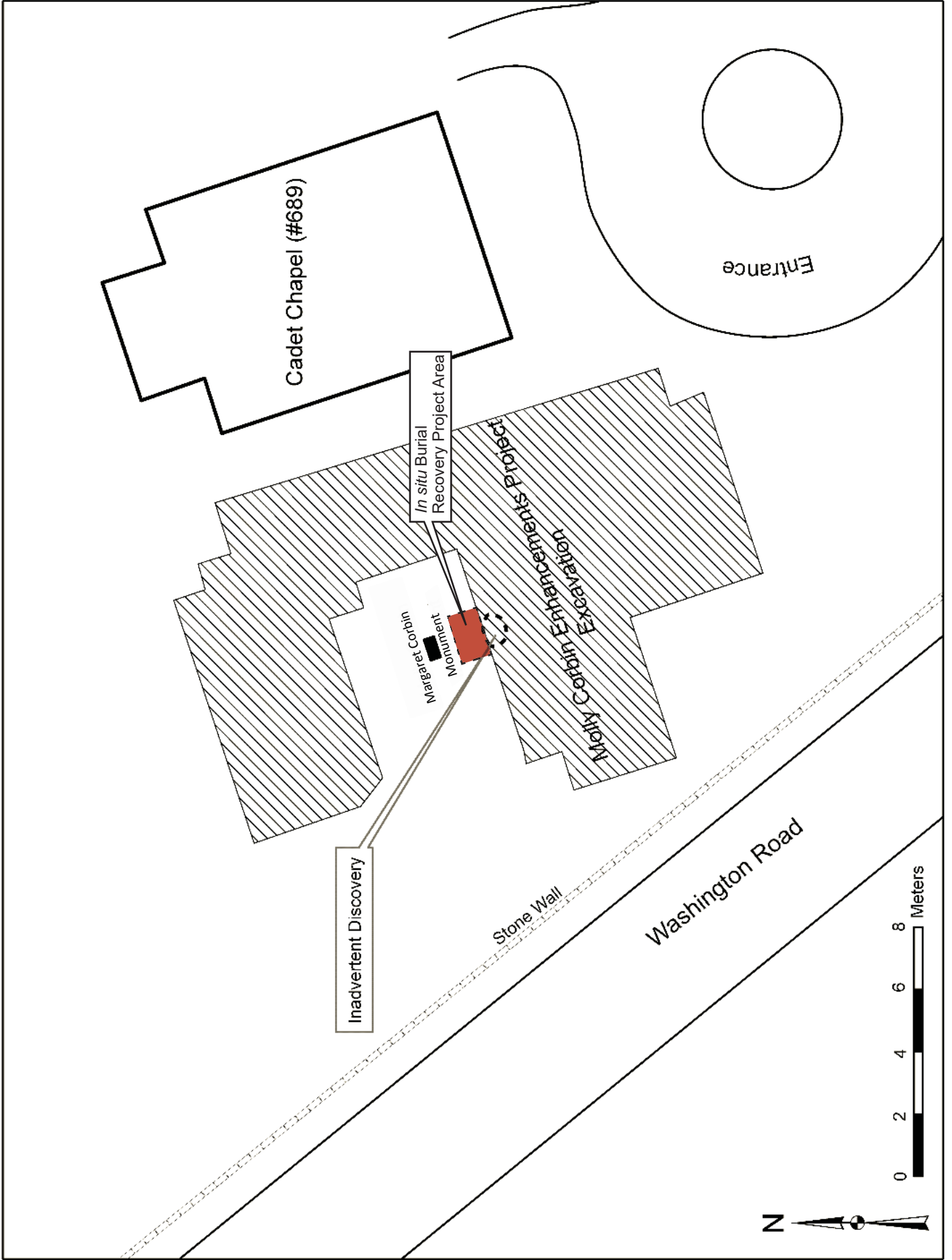


Figure 1. Project area showing original discovery area and *in situ* burial recovery (adapted from Hudson 2016).





Figure 2. Ground surface at the Margaret Corbin Monument (right), showing limits of mechanical excavation at time of burial recovery (courtesy of U.S. Army Corps of Engineers).



Figure 3. Overview of project area showing location of burial, facing northwest.



---

## 2.0 CONTEXT

### 2.1 MARGARET CORBIN

One of the enduring stories of the American War of Independence is that of Molly Pitcher, the wife of a soldier who took his place as an artilleryman when her husband is killed in battle. The story has taken on the trappings of legend in the ensuing centuries, and it is unclear whether the account is factual or who Molly Pitcher really was. While several women are thought to be the real Molly Pitcher, it is likely that her story conflates multiple accounts of women who fought in the war. One of the people who probably inspired the Molly Pitcher legend was a Pennsylvania woman named Margaret Corbin.

The 1915 annual report of the American Scenic and Historic Preservation Society (ASHPS) provides an account of Margaret Corbin's early life. She was born in Franklin County, Pennsylvania, on 15 November 1751. When she was five, her father was killed and her mother captured by Native Americans. Margaret and her brother were not at home when the attack occurred. In 1772, she married John Corbin (ASHPS 1915:142).

John Corbin served in the First Company of the Pennsylvania Artillery under Capt. Francis Proctor (Teipe 1999), and it appears that Margaret accompanied her husband during his time in the field as a camp follower. Camp followers, like Margaret, would have primarily cooked, cleaned and performed other duties in support of the Army. It is unknown if Margaret actively aspired to be a soldier or was thrust into the position by circumstance, but a Congressional resolution dated 6 July 1779 suggests that Margaret Corbin saw significant action at the Battle of Fort Mifflin as a combatant.

In September 1776, a large British force landed in New York City and proceeded to push the Continental Army from its initial defensive lines north along the island of Manhattan. By November, the Americans had fallen back to their final position on the island's northern tip. Their line was anchored by a five-sided earthwork called Fort Mifflin, which was assailed by British forces and their Hessian mercenary allies on 16 November 1776 (BritishBattles.com 2016).

Led by General Sir William Howe, the British attacked from three directions and drove American forces into the fort, pinning the Americans down and compelling them to surrender (Ketchum 1999). The British and Hessians suffered 84 killed and 374 wounded, while the Americans suffered 59 killed, 96 wounded, and 2,838 captured (Ketchum 1999).

During the battle, John Corbin fought as an artilleryman. When John Corbin was killed, Margaret took his place on the firing line and worked the artillery with the other soldiers. Margaret was eventually captured by the British, surviving wounds to her face and shoulder. Paroled shortly after her capture, she was reassigned to the corps of invalids at West Point performing guard duty. A letter from Major Samuel Shaw, an aide-de-camp of Major General Knox, places Corbin at West Point in 1783 (Nelson 1925).

Margaret's injuries were reported to be in the shoulder and breast (Parker 1926), with specific reports indicating that she had been "struck down with three grape shot which nearly severed her arm and a part of her breast" (ASHPS 1917:755). The nature of Corbin's wounds is problematic; while eighteenth-century records indicate she was severely wounded and suffered from these injuries for the rest of her life, the precise extent of these injuries are not reported. The ASHPS reports mention wounding from grapeshot but do not specify on which side of her body Margaret was hit. There are numerous secondary sources and internet articles stating that the grapeshot tore her shoulder, almost severed her left arm, mangled her chest, and lacerated her jaw, but none of these accounts provide references, raising the possibility that her wounds have been exaggerated.

Margaret Corbin is listed on the discharge rolls of the invalid regiment in April 1783 (Teipe 1999). Later, officers from her regiment petitioned successfully for Corbin to receive both state and federal pensions. On 6 July 1779, the Continental Congress "Resolved, That Margaret Corbin, who was wounded and disabled in the attack on Fort Washington, whilst she heroically filled the post of her husband who was killed by her side serving a piece of artillery, do receive, during her natural life Or the continuance of the said disability, the one-half of the monthly pay drawn by a soldier in the service of these states; and that she now receive out of the public stores, one complete suit of cloaths [sic], or the value thereof in money" (quoted from Teipe 1999).

In 1780, the Board of War, "Having information that Margaret Corbin still remains in a deplorable situation in consequence of her wound by which she is deprived of the use of one arm, and in other respects much disabled and probably will continue a cripple during her life, - beg leave to report- Resolved, that Margaret Corbin receive annually during her natural life, one complete suit of cloaths out of public stores, or the value thereof in money, in addition to the provision made for her by the Act of Congress of July 6, 1779" (quoted from Parker 1926).

The state of Pennsylvania also provided Corbin with assistance. In 1779, they awarded her "thirty dollars, to relieve her present necessities, she having been wounded and utterly disabled by three grapeshot while she filled with distinguished bravery the post of her husband, who was killed by her side..." (quoted from Parker 1926).

Parker (1926) documented the letters William Price, Commissary of Military Stores, sent to Major General Knox, Secretary of War, between 1783 and 1790 concerning efforts on behalf of Margaret Corbin.

In 1785 Price wrote:

"I have procured a place for "Captain Molly" till next spring if she should live so long, about three miles from this place, at 12/ per week, and wish you to inform me how the money for the payment is to be come at, and how often she is to be furnished with hospital stores."

---

In January 1786 Price continued:

“I am at a loss what to do with “Captain Molly.” She is such an offensive person that people are unwilling to take her in charge. This woman informs me she cannot keep her longer than the first of March, and I cannot (find) any that is willing to keep her for that money and find her anything to eat and drink. If you should think proper to extend one or two rations to her, it will be better than money and may induce persons to keep her.”

She was one of only two women to receive pensions for military service during the American War of Independence from the Federal Government. Margaret Corbin died at the age of 48 on 16 January 1800 as a result of her war injuries (Teipe 1999). She was buried in a private cemetery at Highland Falls, Orange County, New York.

## **2.2 DAR REINTERMENT AND MEMORIALIZATION**

In 1925, it was determined that if her grave could be located, Margaret Corbin should be reinterred at West Point. Researchers at the time felt they had confidently identified Margaret Corbin as the heroine Molly Pitcher, established that she was assigned to West Point, and that there was no doubt her remains had been identified. Eighteenth century correspondence refer to a “Captain Molly.” Research conducted by the Daughters of the American Revolution (DAR) in the 1920s established that Margaret Corbin was “Captain Molly.”

When Margaret Corbin died in 1800, she was buried in a grave near Highland Falls, New York, approximately 3 miles south of West Point. A 1915 account in the ASHPS annual report locates the grave in Swimtown, the original name for a small hamlet that became Highland Falls. Apparently, late in life Corbin had moved from West Point to Highland. As late as 1904, the location of Corbin’s grave was reportedly still well known to the locals, and in 1916, the ASHPS recorded that a known grave on the Cragston estate at Highland Falls, which local tradition held was that of “Molly Pitcher,” was really that of Margaret Corbin.

The ASHPS 1916 annual report provides additional information:

“There was a blacksmith-shop near the bridge over the brook and not far from where the shop stood are a few graves and a clump of trees. One of these graves the elder Mandigo knew to be Moll Pitcher’s burial place. In the old days everyone in the village knew it and a Mr. Tracy, of the village, put up a sign board on a tree at the head of the grave, after the original bead-board disappeared. This sign-board also disappeared years ago but Peter Mandigo pointed out the grave to me in 1904 (ASHPS 1916:262).”

The DAR conducted research, established a connection between Margaret Corbin and Molly Pitcher, and identified her gravesite. A grave on the Highland Falls property of J. Pierpoint Morgan was identified as the grave of ‘Captain Molly’ (Margaret Corbin). Parker, writing in 1926,



---

recounts, "...On it were two or three graves, one of which was that of "Captain Molly." The grave has remained undisturbed, except for the care given by the superintendent, who has rounded the mound and covered it with periwinkle. It is said that when "Captain Molly" was buried, a cedar tree was planted at the head of her grave and a rough stone or bronze tablet bearing merely two words "Captain Molly." The stump of an old cedar tree was one of the means of convincing the Research Committee that it was indeed the grave of "Captain Molly."

Parker (1926) reports that the DAR established the location of Margaret Corbin's original grave through the recollections of a local resident. "Amos D. Faurot, of Highland Falls, a former Hudson River captain, is authority for the fact that his grandfather assisted in the burial of "Captain Molly," and pointed out the grave to his son. The son in turn pointed it out to interested persons..."

The DAR information was obtained from the 1915 ASHPS report, which, in turn, repeated the account of someone who was told the grave location in 1913. The 1913 account indicates:

Her grave had never been marked otherwise than by a cedar tree which grew beside it, and which, in recent years, had been cut down. The stump, however, yet remained. His father had taken him to her grave and pointing to it said, 'Your grandfather brought me here as I have you', and pointing out her grave said 'Here we buried Molly Pitcher.' Captain Faurot said he had recently marked the grave with a small wooden stave on which he had placed the letters "M.P." (ASHPS 1915:141).

Thirteen years later the DAR took the ASHPS account and was able to find a grave in Highland Falls near a cedar stump (Figures 4 and 5).

The opening of the grave at Highland Falls took place on March 16, 1926. When the grave was uncovered, the bones lay in perfect condition with the right arm by her side and the left hand on the breast. They were imbedded in the earth, as the coffin and garments in which she had originally been buried were rotted away. The skeleton was removed piecemeal and reverently placed in the silk lined casket, until nearly the entire frame of the body had been so assembled.

The surgeon of the West Point Hospital gave the information that the skeleton was that of a female, and that the left shoulder bones bore evidence that they had been injured, verifying history that her shoulder and breast were badly bruised and battered. The surgeon dentist found most of the teeth on both upper and lower jaw on the left side missing, while on the right side they seemed to be worn, which might verify the tradition that Margaret Corbin smoked a clay pipe. (quoted from Parker 1926).

The 1932 Annual Report of the ASHPS contains an article by Edward Hagaman Hall entitled "Margaret Corbin: heroine of the battle of Fort Washington, 16 November 1776." A copy of this



article could not be located, but it is quoted in *Founding Myths: Stories that Hide our Patriotic Past* (Raphael 2004:65), and he describes the disinterment as “A few decayed fibers of wood and several rusty hand-forged nails were the only traces of the coffin... the bones of the skeleton were complete except for the small bones of the feet and the bones of the right hand which had disintegrated.”

### **2.3 WEST POINT CULTURAL RESOURCE MANAGEMENT AND CID EMERGENCY RECOVERY INVESTIGATION.**

On 21 October 2016, construction contractors excavating to install a retaining wall at the Molly Corbin Enhancement Project cut into the remains of a casket in front of the Margaret Corbin Monument. The grave is cataloged as Grave 01 Section 11, Row A. The recovery efforts of CID and West Point Cultural Resource Management (CRM) Staff are detailed by Hudson (2016).

The construction company immediately contacted the Project Manager for the Molly Corbin Enhancement Project and suspended construction activity. CID agents and West Point CRM staff searched the excavated soil for skeletal remains and associated materials (Hudson 2016) using a ¼ inch (in) mesh screen. The disturbed skeletal material covered an area approximately 6 feet (ft) (1.8 meters [m]) south of the Margaret Corbin Monument and 5 ft (1.5 m) beneath the ground surface, on a 6.5 ft (2 m) wide bench created during excavation. This bench was constructed on the edge of a larger excavation, the southern half of which measured approximately 11.5 ft (3.5 m) deep and 59 ft (18 m) across.

The recovery effort was restricted to the construction area and the portion of the burial exposed and disturbed by the construction excavation (Figure 6). A couple of hundred bones and bone fragments were reportedly recovered from the bench area, and skeletal material was observed in situ in the north profile wall beneath the Margaret Corbin Monument. The exposed bones and portions of the coffin were collected, but remains of the burial in the profile wall were left in place, as they would not be affected by further project activities (Figure 7).

CID and CRM staff screened all soil they could identify as having originated from the grave’s disturbance and examined the areas on the bench surface to the east and west of the initial discovery in order to ensure that as much dislodged skeletal material was collected as possible. No skeletal material was encountered outside of the initial scatter.

All bones and bone fragments removed from the site were taken into custody by the CID agents and placed in secure storage at CID Headquarters. Artifacts that were collected were removed to the Cultural Resource Laboratory.





Figure 4. Daughters of the American Revolution disinterment effort (Parker 1926).



Figure 5. Disinterred remains being placed in a hearse (Parker 1926).



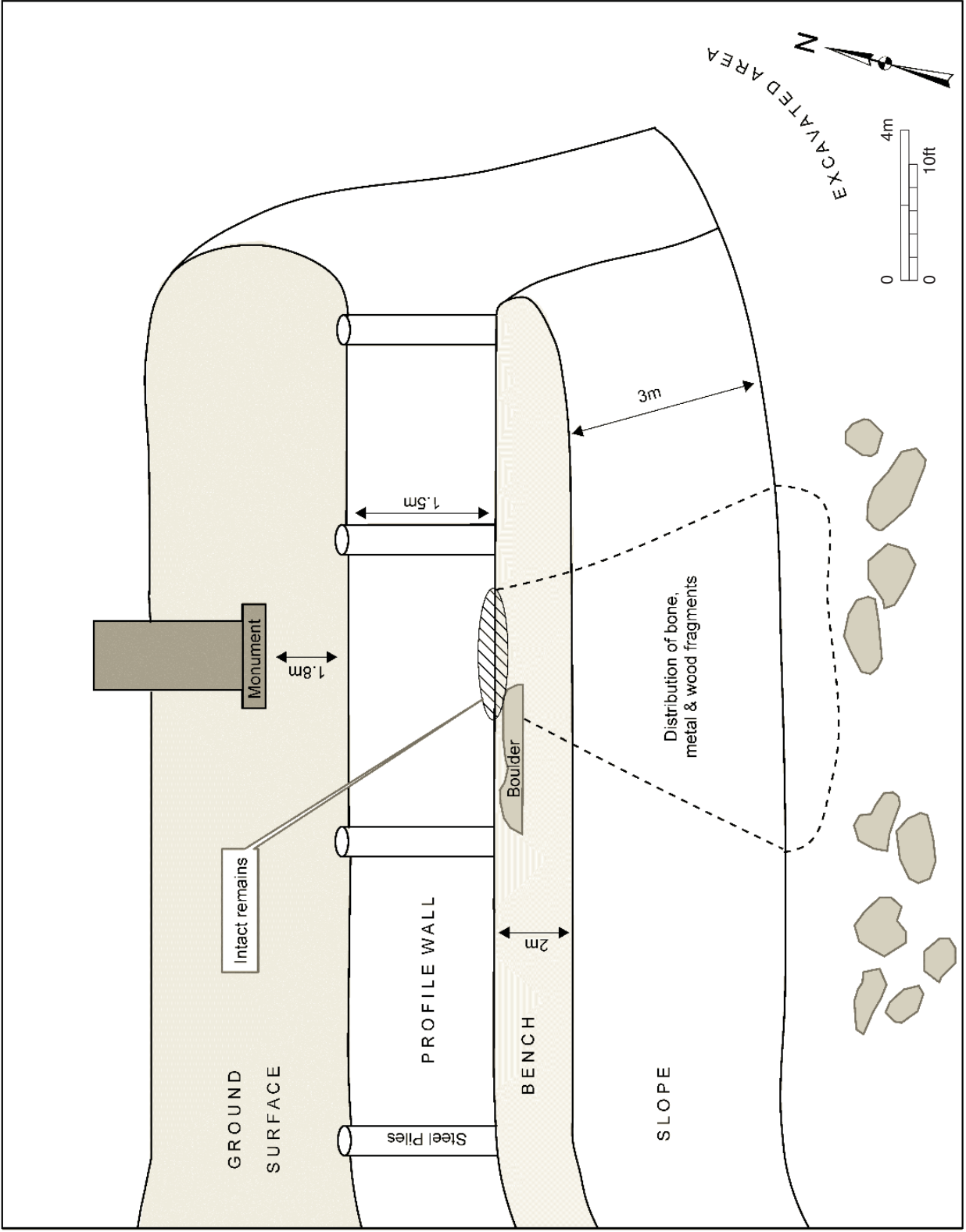


Figure 6. Sketch of inadvertent discovery, showing the distribution of artifacts and remains (Hudson 2016).





Figure 7. Profile exposed by construction contractor, disturbed grave is at base of the profile.





---

## 3.0 FIELD METHODS AND PROCEDURES

The purpose of the investigation was to identify and recover the remnants of a burial that had been disturbed during construction associated with the Molly Corbin Enhancement Project. The project is considered a recovery and not an intensive archaeological investigation. The excavation was designed to comply with New York State Historic Preservation Officer (SHPO) guidelines for a data recovery report, the Secretary of the Interior's *Standards and Guidelines for Archeology and Historic Preservation*, and the West Point Cultural Resource Management program's Standard Operating Procedure (SOP) Procedures for the Discovery of Human Remains and in accordance with the 2016 programmatic agreement with the New York SHPO. The investigation included brief research on the history of Margaret Corbin and her remains and the recovery excavation of the remains in front of the Margaret Corbin Monument.

### 3.1 FIELD METHODS

Field methods included mechanical and hand excavations. A backhoe, provided by the West Point Department of Public Works, was used to remove overburden from above the grave. Once the excavation was within 0.65-1.0 ft (20-30 centimeters [cm]) of the top of the burial, the remaining overburden was removed by hand. The burial was excavated by hand, with a trowel used to remove the fill directly above the coffin, and wood and bamboo tools used to excavate the coffin matrix and expose the bones with minimal damage.

All soils excavated from the burial itself were screened through 1/8th in hardware cloth to recover small bone fragments. Because the purpose of this excavation was solely to recover the skeletal remnants that were not disturbed during the coffin's initial exposure, a decision was made to note artifacts in the field and not collect them. Coffin hardware was identified, photographed, and left in the field. When skeletal remains were encountered, they were wrapped in acid-free paper and placed in labeled acid-free boxes. Small bones and fragments recovered during screening were placed in plastic bags for later sorting and identification. The skeletal material was brought to an office in the West Point Cemetery Administration building where the material could dry. This material remained in this office until the forensic anthropologist took possession of the remains. The forensic anthropologist also took possession of the skeletal material and artifacts held by the CID.

Digital images were taken during the field investigations. The location of the burial was recorded using a GPS with sub-meter accuracy.

### 3.2 LABORATORY AND ANALYSIS METHODS

No artifacts were retained during this investigation.

Previously, CID officers and West Point CRM archaeologists collected artifacts, including coffin hardware, as part of their recovery effort. These artifacts were returned to CHG's Alexandria, Virginia office where they were counted and a representative sample was photo-documented. The

cataloging to the standards set forth in 36 C.F.R. Part 79 and the guidelines of the intended repository was not undertaken by CHG. The artifacts will be returned to West Point.

The skeletal material recovered during this investigation and by the previous one were signed over to Elizabeth A. DiGangi, Ph.D., a certified member of the American Board of Forensic Anthropology® and Assistant Professor of Anthropology, Binghamton University, State University of New York for analysis. Appendix IV contains her report.

Because the analysis the skeletal material raised questions on the sex of the remains, DNA testing was undertaken to conclusively determine whether the burial was male or female. DNA testing was conducted by D. Andrew Merriwether, Ph.D., Associate Professor of Anthropology and Biology Chair of Anthropology Binghamton University, State University of New York. Appendix V contains his DNA report.

---

## 4.0 FIELD WORK

The emergency recovery by MCX CMAC and CHG staff was undertaken between 29 November and 3 December 2016 (Figure 8). The recovery included identifying the approximately one-third of the burial that remained undisturbed, recovering the remaining skeletal material, and recording the burial.

The gravesite was located between two steel pilings placed approximately 6 to 7 ft (1.83-2.13 m) south of the Margaret Corbin Monument. Construction activities had created a sloping wall that cut up to 2.5 ft (0.75 m) behind the steel pilings (Figure 9). Previously, the burial disturbed by construction and the area immediately adjacent and under the disturbed burial was thoroughly investigated. Additionally, no evidence of the in situ burial was observable in the profile.

Under the direction of CHG archaeologists, the overburden above the remaining part of the casket was mechanically removed to within 0.65-1.0 ft (20-30 cm) of the top of the burial. The area excavated was restricted to the approximately 6 ft (1.83 m) between two steel pilings (Figure 9). To expose the whole burial, the mechanical excavations extended back to within 3.5 ft (1.07 m) of the Margaret Corbin Monument. This allowed for the casket to be fully exposed.

### 4.1 PROFILE

The original excavation profile did not show a distinct grave shaft, but one was undoubtedly present. The stratigraphy evidenced by this profile included a developing A horizon, construction fill, and a deposit of boulders (Figure 10). The soil matrices into which the grave was dug consists of fill obtained from different construction locations on West Point around 1910, when the Old Cadet Chapel was relocated to the West Point Cemetery. An approximately 1.5 ft disturbed soil deposit consisting of dark brown sandy loam overlies the grave shaft. This stratum was deposited after the existing Margaret Corbin Monument was erected in 1926. A fill deposit consisting of yellowish brown sandy loam mottled with approximately 20 percent brown sandy loam with gravels and cobbles forms an approximately 3.3 ft (1 m) thick deposit between the dark brown sandy loam and underlying deposits of sand or boulders. Early twentieth century artifacts observed within this fill deposit include wire nails and bottle glass. Underlying this sandy fill is an approximately 0.5 ft (14 cm) deposit of very dark grey fine sand mottled with (~20 percent) and overlain by white fine sand. Beginning at 5 to 5.5 ft (1.5 to 1.68 m) below the ground surface is a deposit of boulders. The boulders were deposited in this location by human activity and the spaces between were not originally filled in with soil. As a result, large voids are present between the boulders, and objects observed within the voids include twentieth century glass bottle fragments, nails, and iron sheet-metal fragments. The base of the casket rests on this deposit of boulders. It is not clear if the grave diggers stopped when they encountered the boulders, if boulders were removed to accommodate the casket, or if the casket was placed at an angle within the grave shaft to avoid boulders.

The top of the grave shaft is approximately 3.3 ft (1 m) wide and it tapers to approximately 18 in (45.7 cm). The base is just the width of the casket (Figure 10). The matrix within the grave shaft

is redeposited fill. Since the grave shaft was opened and closed within a short time span the outline of the grave shaft is not distinct. The matrix within the shaft is nearly identical to the fill deposit it was dug into, except that there were fewer large rocks within the grave shaft fill. The only artifact observed within the grave shaft was a whole mold-blown clear glass bottle embossed “Warrented Flask.” This bottle type dates from between the mid to late 1890s until at least 1920 (Lindsey 2016). The top of the grave shaft was not clearly defined as the 1926 ground surface was not identified. At present the base of the casket is 5.5 ft (1.68 m) below the present ground surface. There is no evidence that fill was added later to flatten the grave after it had settled.

Prior to recovery of the skeletal material from within the casket, the area immediately west of the casket was excavated and screened to assure that no disturbed remains were in this area.

## **4.2 BURIAL**

The recovery effort determined that construction activity had destroyed approximately 2/3rds of the burial. The part of the burial that survived was the upper third of the casket closest to the Margaret Corbin Monument, and provides enough information to determine the dimensions of the casket. Only the metal lugs and the rails of the casket have survived more or less intact (Figures 10 and 11); all wood and fabric from the reinternment has deteriorated. The casket appears to have been 1.5 ft (45.7 cm) wide and had wooden rails sheathed in iron and capped with ornamented lead finials running its entire length. The rails were connected to the casket by iron lugs, which have since rusted to the metal sheathing of the rails. On the west side, only one lug and 15 in (38 cm) of bar were identified during the recovery, however the initial recovery efforts by CID and West Point CRM staff included the removal of skeletal material and partial rails from this area due to their exposure during construction. The east side of the casket included two lugs and in situ rail fragments extending for 39.5 in (1.33 m).

Skeletal material was recovered from the interior portion of the casket (Figures 12 and 13). The in situ portion of the casket contained both humeri, vertebrae, cranial fragments, a mandible, and scapula fragments. The skeletal material appears to have been anatomically arranged in the casket at the time of reinternment. The cranium was closest to the end of the casket, with the humeri arranged on either side and the surviving scapula in rough anatomical position below and to the right of the cranium. There appears to have been some movement of the skeletal material after it was placed in the casket, as smaller elements were mixed up in the area between the cranial elements and the humeri.

Because this investigation was a recovery and no research questions regarding burials were necessary to address for this internment, the skeletal remains were not mapped in place. Photographs were taken to record the recovery efforts. Recovery and excavation of the skeletal material was undertaken by an experienced burial excavator using standard operating practices for uncovering fragile bone. Only wood tools were used and the bones were carefully exposed to avoid unnecessary stress before they could be transferred to the appropriate boxes. Once removed from the casket, skeletal material was promptly transferred in the West Point Cemetery Administration

---

building. All matrix within the casket was screened through 1/8<sup>th</sup> in mesh screen to assure the recovery of all skeletal material.

Artifacts observed within the casket included casket hardware (lugs and rails) and casket nails. A decision was made in the field by CHG, MCX CMAC, and the client to leave all artifact material in the field, as these artifacts were associated with the 1920s reinternment and would not contribute to our understanding of Margaret Corbin or significant aspects of her life. Further, the CID and West Point CRM staff collected a sample of the casket hardware during their initial recovery that will be retained at West Point. Casket hardware encountered during the recovery was photographed but not retained. The casket in which the remains were reinterred measured 5.5-by-1.5 ft. (1.68-by-0.46 m) (Figures 14 and 15), with the first lug located 5 in (12 cm) from the end of the casket. Each lug is 7 in (18 cm) long, and the width between the first and second lug (the only two consecutive lugs observed in situ) is 17.5 in (44 cm). In total, four whole lugs and parts of two fragmentary lugs were observed. Therefore, the casket would have been 5.5 ft (1.68 m) long. The casket appears to be a common type from the early twentieth century (Figure 16). It is of simple construction, is not ornate, and possesses three lugs on each side that together hold a long handle.

The depth of the casket could not be determined because no evidence for the top has survived. The thickness of deposits containing skeletal material within the casket was approximately 0.5 ft (15 cm).

### **4.3 FORENSIC ANALYSIS**

The recovered remains were subjected to an osteological analysis by a board certified forensic anthropologist. The remains were evaluated for minimum number of individuals, age at death, sex, ancestry, stature, trauma, pathology, and postmortem modifications. This is the typical suite of analyses that can be carried out on skeletal remains in this kind of setting.

The remains were fragmentary but represented a mostly complete single adult individual (being approximately 85-90% complete). The analysis revealed that the remains are that of an adult male, who was 45 years or older at his death. Ancestry was undeterminable due to postmortem damage to the facial skeleton and skull, the areas most important for ancestry estimation. However, it is likely that the individual was either of European or African ancestry based on context. Based on measurements of his long bones (arm and leg bones), he stood between 5'7" and 6'6", and was likely closer to 6 feet tall. Based on context, he has been dead at least 150 years.

The estimate of male is supported by several lines of evidence. The skeleton is very robust, with marked development of muscle lines where the muscles attach to the bones. Several features of the pelvis and skull also support an estimate of male, and measurements taken of the bones and compared to measurements of known males and females all indicate male. There were no features that would be consistent with that of a female.

The individual had several health conditions during life, including dental disease, arthritis in several joints, and a fractured foot which led to a serious bone infection. He had also possibly suffered from a fractured arm as a teenager and a fractured lower back as an adult. Evidence from the present teeth indicate that he had habitually smoked a pipe.

None of the traumatic conditions Margaret Corbin was known to have had (serious arm and shoulder trauma from the Battle of Fort Washington in 1776) were present. The shoulder and arm bones were anatomically normal and only exhibited postmortem damage consistent with casket burial for a long period of time. This damage is what the West Point surgeon who examined the remains in 1926 likely mistook for trauma that had occurred during life.

#### **4.4 DNA ANALYSIS**

Three elements from the excavated remains were given to the Merriweather Ancient DNA and Forensic Laboratory at Binghamton University to confirm the individual's sex. These elements consisted of one tooth, one femur, and one phalange. Viable samples were subjected to testing of the amelogenin gene and mitochondrial DNA (mtDNA). Amelogenin is a gene present on both the X and Y chromosome that does not cross-replicate, allowing researchers to identify whether a tested sample includes amelogenin from the Y chromosome. Presence of Y chromosome amelogenin indicates a sample comes from a biological male. MtDNA is a matrilineally-inherited sequence of genes that allows researchers to determine a sample's probable ancestry. All efforts up to accepted standards were taken to prevent modern contamination.

Three clean samples were extracted and tested using amelogenin primers, which can detect a 6 pb deletion that indicates whether the amelogenin gene comes from an X or Y chromosome. The amelogenin sequence from the samples showed the presence of amelogenin from a Y chromosome, proving that the sample comes from a biological male.

Three specific regions of the mtDNA were sequenced to determine the individual's probable ancestry. The three partial mtDNA sequences indicated that the individual comes from haplogroup M (M6a1a), C (C1a), and N (N1a2). Haplogroups M (M6a1a), C (C1a), and N (N1a2) have a wide distribution in Europe and Asia and are not seen in indigenous African populations. To further narrow down the haplogroup, more of the mtDNA will need to be sequenced.



Figure 8. Overview of project area during recovery, facing northeast.





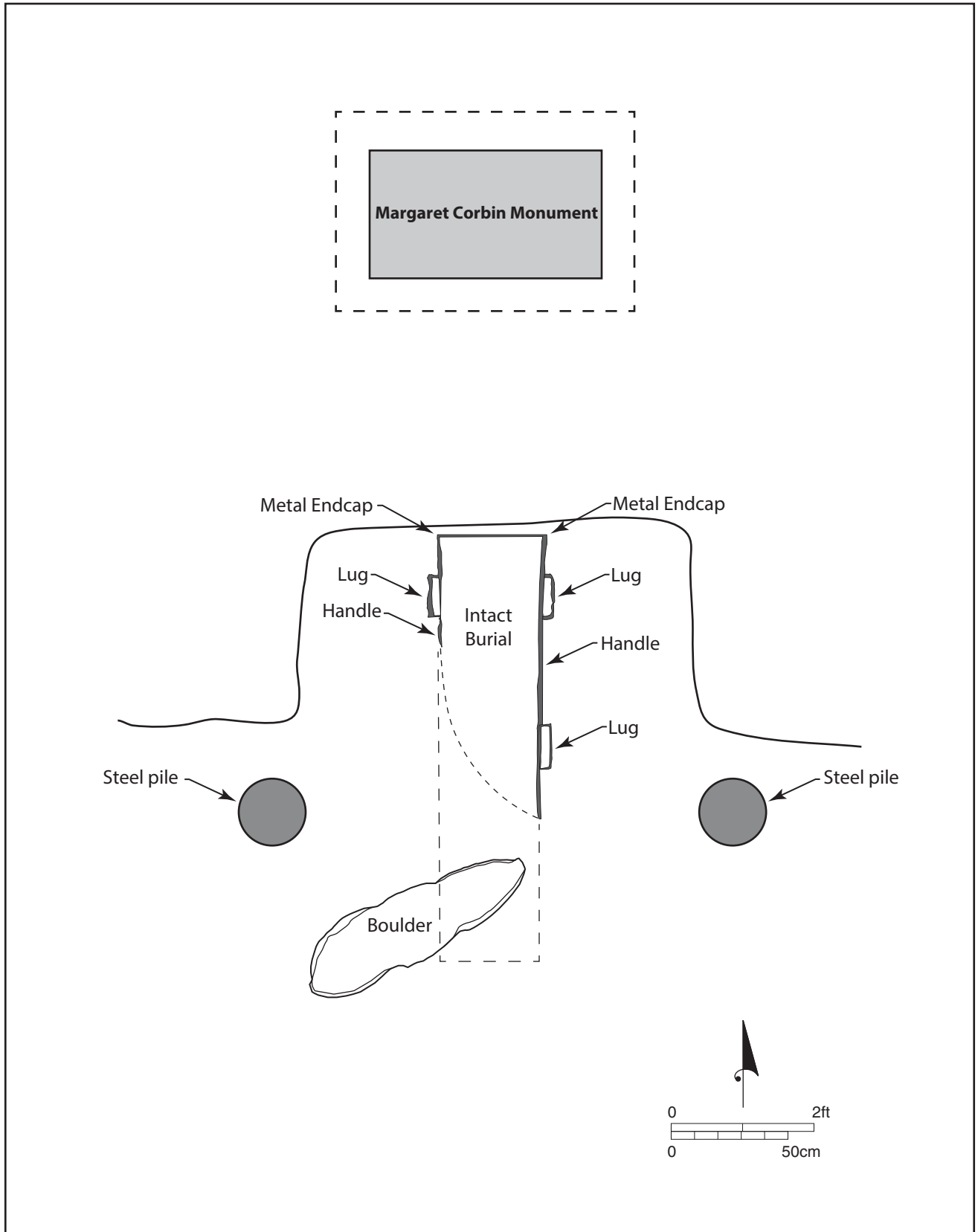


Figure 9. Plan view of burial.





Figure 10. View of casket after skeletal material removed. Profile shows indistinct grave shaft and fill, facing north.



Figure 11. Unexcavated burial showing casket hardware, facing north.





Figure 12. Excavation in progress.



Figure 13. Excavation of skeletal material.







Figure 14. Exposed burial showing casket remnants after excavation, facing north.



Figure 15. Casket hardware: lug and rail.





## 5.0 SUMMARY

The MCX CMAC was asked to support the emergency forensic archaeological recovery and disinterment of an individual buried in the West Point Cemetery. The cemetery is located at 329 Washington Rd, West Point, New York 10996. The burial is Grave 01, located at the West Point Post Cemetery, West Point, Orange County, New York, in Section 11, Row A. Staff from Commonwealth Heritage Group, Inc. (CHG) conducted the investigation for SKY-CHG JV. SKY-CHG also managed the post-excavation skeletal analysis undertaken by a board certified forensic anthropologist (certified through the American Board of Forensic Anthropology®) and subsequent DNA analysis.

Contractors excavating to install a retaining wall at the Molly Corbin Enhancement Project disturbed a grave (Section 11, Row A, Grave 01) located directly in front of the Margaret Corbin Monument. CID and West Point CRM staff removed all remains and associated artifacts exposed by excavation machinery. CID took possession of the recovered skeletal remains and associated artifacts.

The emergency recovery by MCX CMAC and CHG staff was undertaken between 29 November and 3 December 2016. The recovery included exposing the burial's undisturbed remnants, recovering the remaining skeletal material, and recording the burial.

Sex identification is based on well-established statistical procedures and extremely reliable attributes on particular bones. While the innominate bones were not recovered intact, the initial fragments given over to CID custody included a fragmentary pubis and part of the right sciatic notch, both of which are reliable indicators of an individual's sex. The cranial morphology and muscle attachments on the long bones support a male identification, and indicate that the individual was both relatively tall and heavily muscled. Post excavation analysis of the skeletal material indicates that the individual interred in the grave is likely a male. Amelogenin-based DNA testing confirms the individual is a male from haplogroup M, C, or N, probably of European or Asian descent.



---

## 6.0 REFERENCES CITED

### American Scenic and Historic Preservation Society (ASHPS)

- 1915 Twentieth Annual Report of the American Scenic and Historic Preservation Society. To the Legislature of the State of New York. Founded by Andrew H. Green and incorporated by the Legislature of the State of New York, 1895. No. 154 Nassau St, New York. NY. Printed by J.B. Lyon Company, Albany, NY.
- 1916 Twenty-First Annual Report of the American Scenic and Historic Preservation Society. To the Legislature of the State of New York. Founded by Andrew H. Green and incorporated by the Legislature of the State of New York, 1895. No. 154 Nassau St, New York. NY. Printed by J.B. Lyon Company, Albany, NY.
- 1917 Twenty-Second Annual Report of the American Scenic and Historic Preservation Society. To the Legislature of the State of New York. Founded by Andrew H. Green and incorporated by the Legislature of the State of New York, 1895. No. 154 Nassau St, New York. NY. Printed by J.B. Lyon Company, Albany, NY.
- 2016 BritishBattles.com  
Battle of Fort Washington. BritishBattles.com.  
<http://www.britishbattles.com/fort-washington.htm>. Accessed 19 December 2016.
- 2017 etsy.com  
Vintage Photo Dust Bowl Men Grieve over Casket 1920 Texas Funeral. etsy.com.  
<https://www.etsy.com/listing/104599460/vintage-photo-dust-bowl-men-grieve-over>. Accessed 24 January 2017.

### Hudson, Paul

- 2016 Report on the Inadvertent Discovery of Cultural Resources Associated with the Molly Corbin Enhancement Project, U.S. Military Academy, West Point, New York. USAG West Point Cultural Resources Program. Document on file, St. Louis Corps of Engineers, St Louis, MO.

### Ketchum, Richard

- 1999 *The Winter Soldiers: The Battles for Trenton and Princeton*. Henry Holt and Companies, New York New York.

### Lindsey, Bill

- 2016 Liquor/Spirits Bottles. Historic Glass Bottle Identification & Information Website. Bureau of Land Management and Society for Historical Archaeology.  
<https://sha.org/bottle/liquor.html>. Accessed 13 December 2016.

---

New York Archaeological Council

- 1994 *Standards for Cultural Resource Investigations and the Curation of Archaeological Collections in New York State*. The New York Archaeological Council All rights reserved.
- 2000 *Guidance for Understanding and Applying The New York State Standards for Cultural Resource Investigations*. The New York Archaeological Council

Nelson, Peter

- 1995 Letter to Mrs. Alton B. Parker dated December 15, 1925. Correspondence on file St. Louis Corps of Engineers, St Louis, MO.

Parker, Amelia Campbell

- 1926 Revolutionary War Heroine Interred in West Point Cemetery. Daughters of the American Revolution Magazine. Copy on file St. Louis Corps of Engineers, St Louis, MO.

Raphael, Ray

- 2004 *Founding Myths: Stories that Hide our Patriotic Past*. The New Press, New York.

Teipe, Emily J.

- 1999 Will the Real Molly Pitcher Please Stand Up? Prologue Magazine, Summer 1999, Vol. 31, No. 2. <https://www.archives.gov/publications/prologue/1999/summer/pitcher.html>. Accessed 14 November 2016.

APPENDIX I

Artifact Catalog

Prepared by W. Brett Arnold, RPA









## APPENDIX II

# SELECTED ARTIFACT PHOTOGRAPHS





Figure 1. Fragments of casket lug.



Figure 2. Casket lug with partial rail.





Figure 3. Lead tabs, possibly part of casket.



Figure 4. Rail fragment with finial.







Figure 5. Decorative metal object, possibly part of casket.



Figure 6. Casket rail fragment.







Figure 7. Casket lug and rail fragment, including rail finial.



Figure 8. Casket lugs and rail fragments from east side of coffin.





Figure 9. Casket rail fragments from east side of casket.



Figure 10. Casket lugs from east side of casket.







Figure 11. Casket rail fragment.



Figure 12. Casket lug fragment.



## APPENDIX III:

# West Point Cultural Resources Program Report





**Report on the Inadvertent Discovery of Cultural Resources  
Associated with the Molly Corbin Enhancement Project,  
U.S. Military Academy, West Point, New York**

**Paul Hudson**

**Archaeologist**

**USAG West Point Cultural Resources Program**

**October 21-26, 2016**

## **CHRONOLOGY OF EVENTS**

On the afternoon of Friday, October 21, 2016, West Point Cultural Resource Management archaeologist Pat Raley was contacted by Paul Franco, Project Manager for the Molly Corbin Enhancement Project, who advised that skeletal remains suspected to be human had been uncovered during excavation for the project. Mr. Franco further advised that upon discovery, all excavation activities were ceased and would not continue until further direction was received concerning the remains. Following the West Point Cultural Resource Management program's SOP *Procedures for the Discovery of Human Remains* and in accordance with the 2016 programmatic agreement with the New York State Historic Preservation Officer (SHPO) and the 2014 Memorandum of Agreement with the Stockbridge-Munsee Band of Mohican Indians, Mr. Raley notified the West Point Military Police, who dispatched a patrol unit to the location to secure the scene. Mr. Raley then notified the West Point Provost Marshal's Office, the New York State Historic Preservation Officer, the Stockbridge-Munsee Band of Mohican Indians Tribal Historic Preservation Officer (THPO), and the West Point Public Affairs Office.

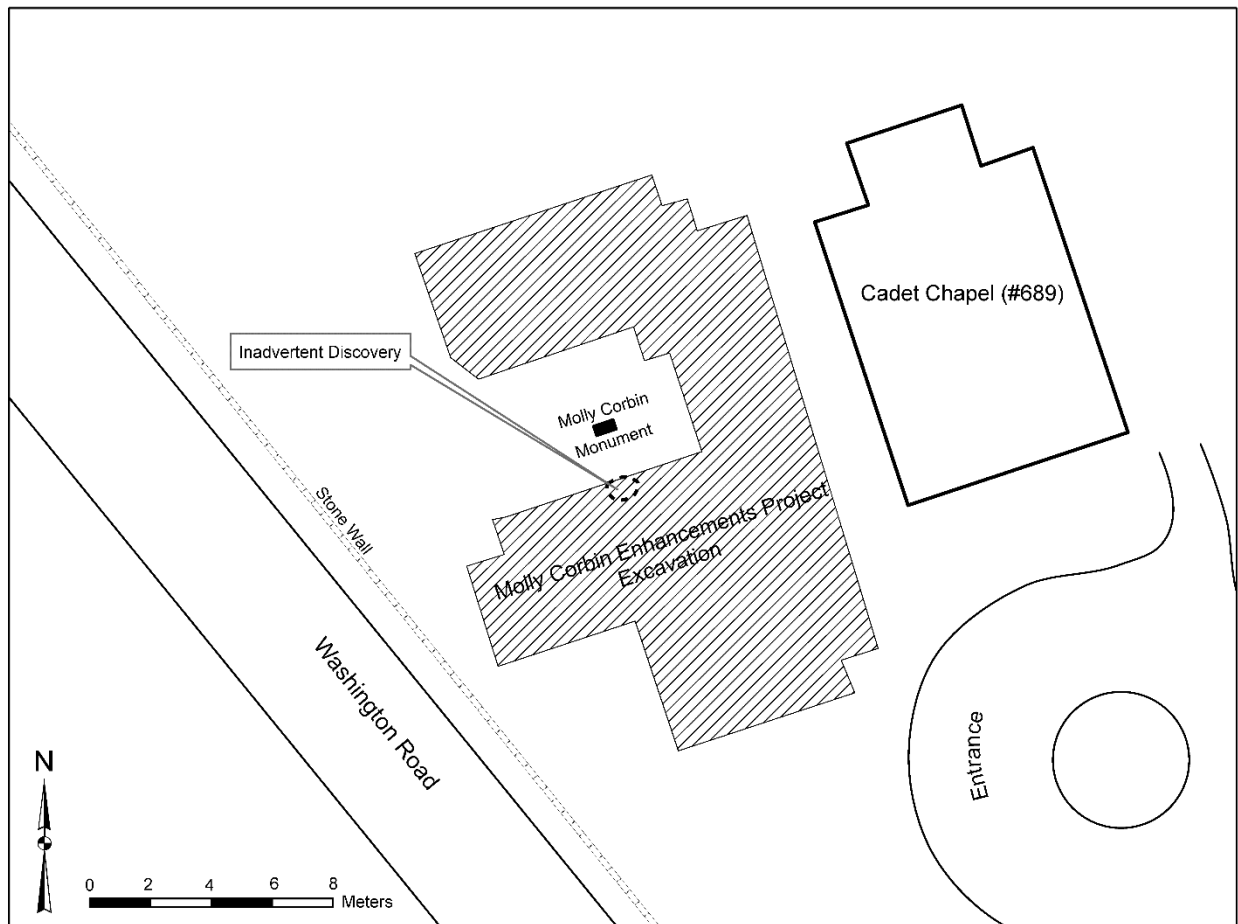
Having secured the scene, West Point Military Police informed West Point Criminal Investigation Division (CID) agents, who contacted the office of the Orange County Coroner. Per the West Point CRM's SOP, West Point CID is responsible for confirming that the remains are human and making the legal determination that they either constitute a crime scene or are archaeological/historic in nature. The Orange County Coroner not being available, the CID was initially unable to make this determination and, in consultation with the West Point CRM staff, contacted physical anthropologist Dr. Jill Shapiro, member of the faculty of the anthropology department at Columbia University in New York City, to verify that the remains were human and whether they constituted a crime scene or were archaeological/historic in nature.

CID agent Sarah Fonville removed the initially uncovered remains and transported them to Dr. Shapiro at Columbia University. Mr. Raley observed a metal artifact associated with the uncovered remains that appeared to be a fragment of coffin hardware. He then contacted the New York SHPO and the Stockbridge-Munsee Band of Mohican Indians THPO and advised them that the remains appeared to be historic in nature.

On October 24-26, 2016, CID agent Fonville and staff, assisted by West Point CRM archaeologists Pat Raley and Paul Hudson, removed all remains and associated artifacts in the project's area of potential effect (APE).

## REMOVAL OF REMAINS

On Monday, October 24, 2016, CID agents Fonville and staff, assisted by Mr. Raley and Mr. Hudson, began removal of the suspected human remains uncovered during excavation for the Molly Corbin Enhancement Project. Project Manager Paul Franco advised that the remains were exposed by a large hydraulic excavator in the project area in the southern portion of the cemetery. The remains were located west of the Cadet Chapel (#689), approximately 1.8m south of the Molly Corbin Monument and 1.5m beneath the ground surface, on a 2-meter-wide bench created during excavation, on the edge of a larger excavation, the southern half of which measured approximately 3.5m deep and 18m across (see Figure 1). The remains initially uncovered by the excavator, consisting of 2 tibiae and several ribs, were situated on the surface of the bench between two steel pilings located on either side of the monument. On inspecting the site on October 24, several fragments of unidentified bone were observed on the surface of the soil embankment below the bench extending to the bottom of the larger excavation.

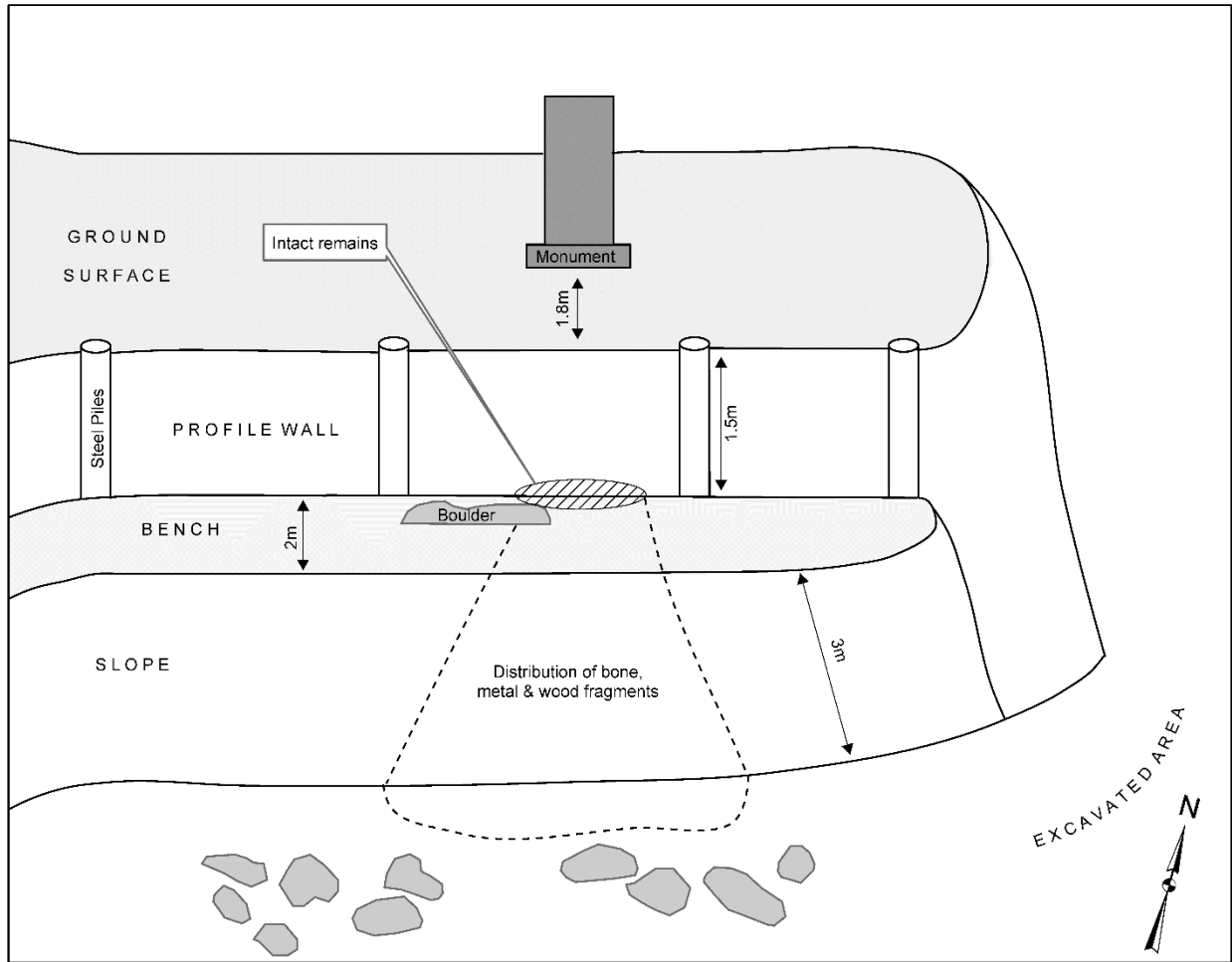


**Figure 1. Plan view of excavations for the Molly Corbin Enhancement Project.**

Mr. Franco advised that no soil had been removed from the site the previous Friday, when the remains were uncovered, and that all of the soil removed from the bench in the area of the remains lay at the bottom of and on the surface of the slope directly below the bench. Based on this information, it was decided to first effect the recovery of the remains in the soil below the bench, beginning with the accumulation of soil at the bottom of the slope. This consisted of the removal by hand of large rocks, the removal and collection of disturbed soil, and the sifting of soil through a standard ¼-inch screen. Because much of the cemetery consists of fill that has been deposited from different areas of West Point, historic artifacts such as fragments of glass, metal, ceramic, and brick are common in the subsurface soils. Consequently, it was decided that only artifacts found directly in association with bone or bone fragments would be recovered.



**Figure 2. Profile view of inadvertent discovery showing the monument, north profile, bench, and slope.**



**Figure 3. Sketch of inadvertent discovery, showing the distribution of artifacts and remains.**

Following the sifting of the accumulated soil at the bottom of the slope below the bench, the remains and artifacts on the soil on the surface of the slope were collected. The soil was carefully scraped away with trowels to intact, recently undisturbed soil and sifted as well. Throughout the process, the CID agents photographed bones and bone fragments as they were encountered. It was found that these were distributed in a cone-shaped pattern, with the initially-exposed remains on the bench surface at the apex. This pattern indicated that the bone fragments found below the bench had originated in the concentration of bones on the bench surface.

On Tuesday, October 25, 2016, sifting of the excavated soil below the bench was completed by CID agents and CRM archaeologists. Approximately 50 bones and bone fragments were recovered from this area, and approximately 100 artifacts in association with the fragments were recovered, consisting entirely of metal fragments.

Next, removal of remains from the bench surface was begun, with the goal of recovering the remaining bones disturbed by project excavation and determining whether additional materials remained intact and, if so, their spatial extent. Removal was undertaken with trowels, brushes, and finer hand tools, all soil removed was sifted through ¼-inch screen, and uncovered remains were photographed *in situ* by CID agents.

Removal of the soil on the bench disturbed by the excavator revealed additional bones and metal fragments in soil not directly disturbed by the excavator. These remains were carefully collected as well, and the soil on the bench was removed to a depth of 20cm below the deepest identified bone or bone fragment. Sediments in the northwestern portion of the bench adjacent to the north side of a large granite boulder were removed to a depth of approximately 40cm below the surface of the bench, as bioturbation observed in that area might have displaced bones or bone fragments to a greater depth. No displaced remains were encountered. Approximately 100 bones and bone fragments were recovered from the top of the bench. These included fragments of vertebrae and ribs, as well as tarsals that were nearly entirely articulated. Many of the ribs and vertebrae presented recent fractures, likely due to the disturbance of the soil by excavator. Approximately 40 artifacts associated with the remains were also recovered, consisting primarily of metal fragments, including 2 metal buttons and a small metal cog, but also a smaller number of wood fragments,

At this time, it was also found that bones in the intact deposits exposed on the bench extended into the north profile wall of the excavation, into soil that would not be affected by further excavation for the project. It was determined by the CID agents, in consultation with Mr. Raley and Mr. Hudson, that, if possible, the bones and artifacts protruding from the profile wall onto the bench would be recovered, as these would potentially be affected by further project excavation. It was decided that any additional bones or artifacts encountered within the profile wall would be left *in situ*, as they would not be affected by further project activities and would be protected by shoring that would be installed between the steel pilings in front of the profile wall, as part of the original project plans.

Three long bones and some smaller bones were removed from the bench and profile wall, consisting of two femurs, a radius, and several carpal bones. At least two additional unidentified long bones were observed embedded within the profile wall but were left *in situ*, as they would not be impacted by further project activities. In addition, several small fragments of a light blue woven cloth were recovered from the profile wall in the area between the two femurs, and two metal and wood artifacts associated with the long bones and extending onto the bench were removed from the profile wall. The latter consisted of two segments of long, square metal tubing with wood interior and rectangular metal attachments. The spaces created by the removal of bones and artifacts from the profile wall were packed with sifted soil to prevent further disturbance to the remaining bones.

On Wednesday, October 26, 2016, CID agents and CRM archaeologists completed the sifting of removed soil, and the areas on the bench surface to the east and west of the initial discovery were explored in order to insure that all remains in the impacted area had been recovered. No remains were encountered outside of the initially identified distribution cone.

All bones and bone fragments removed from the site were taken into custody by the CID agents and placed in secure storage at MP Headquarters. Artifacts that were collected were removed to the Cultural Resource Laboratory (#675).

## **DISCUSSION**

The recovered remains found *in situ* on the bench (including the exposed portions of those extending into the profile wall) covered an area measuring approximately 0.5m north/south by 0.8m east/west, to a maximum depth of 1.5m below the surface. This area was located entirely in the space between the two steel pilings driven into the ground prior to the inadvertent discovery. There was no indication that the pilings had affected the remains.

The position of the intact remains suggests that they were not fully articulated when interred. The only discernible pattern of distribution consisted of groupings of like bones. The femurs were lying parallel to one another approximately 10 cm apart, with carpal bones grouped together between them. The majority of ribs and vertebrae were located adjacent to the femurs on the south, presumably near or possibly below the tibiae, which were disturbed by the excavator. Some bioturbation was observed. Small root growth had minimally impacted the remains, and a rodent burrow was located approximately 15cm beneath the intact remains and extending beneath a large, sub-angular granite boulder adjacent to the southwest edge of the undisturbed area.

The sediments in which the remains were found were variable due to the historical development of the cemetery, which consisted of the depositing of sediments from other areas on post in order to create a flat, stable surface. Undisturbed remains were encountered in semi-loose brown loam grading downward into semi-compact yellow-brown sandy clay mixed with gravel, the latter likely undisturbed soil original to the cemetery area. In addition, small lenses of semi-compact ashy clay were encountered, as well as larger lenses of loose, brown sandy loam, with one located directly above the intact remains.

Metal and wood artifacts found in association with the remains indicate that they were interred in a receptacle, although the original size and shape are difficult to infer, since only a portion of the artifacts and remains were recovered. The fragments of woven cloth recovered from the profile wall may have been a lining, and the two segments of metal tubing with wood interior encountered in the profile wall, as well many of the metal

artifacts found on and below the bench, may be the remains of a coffin, although it appears to have collapsed over time. Given the variable nature of the sediments, it is very likely that some shifting occurred since the time that the remains were interred, particularly as the receptacle containing them decomposed. Nevertheless, the disarticulation of the remains and their distribution into groups is suggestive of a secondary burial.



## APPENDIX IV

# Forensic Anthropologist Report



## **REPORT OF OSTEOLOGICAL ANALYSIS**

**DATE:** January 26, 2017

### **REPORT SUBMITTED TO:**

Joseph Balicki, RPA, Regional Director  
Commonwealth Heritage Group  
5250 Cherokee Avenue, Suite 300  
Alexandria, VA 22312  
jbalicki@chg-inc.com  
(703) 354-9737 ext. 212

### **REPORT SUBMITTED BY:**

Elizabeth A. DiGangi, PhD, D-ABFA  
Assistant Professor  
Department of Anthropology  
Binghamton University 4400  
Vestal Parkway East  
Binghamton, NY 13902  
digangi@binghamton.edu  
(607) 768-9878 (cell)

### **BACKGROUND INFORMATION OF SKELETAL ANALYSIS**

This report contains my findings with regard to the skeletal remains recovered from the disturbed coffin underneath the Margaret Corbin memorial monument at the United States Military Academy in West Point. On November 8<sup>th</sup>, 2016, Jackie Rector, physical anthropologist for the US Army Corps of Engineers-St. Louis, contacted me via email requesting my possible assistance with a case of theirs. Following that initial correspondence, I spoke via telephone with Dr. Michael "Sonny" Trimble about the specifics of the case. Evidently a coffin in association with the Margaret Corbin monument had been accidentally disturbed by ongoing construction work. The disturbed remains were collected by Criminal Investigative Division personnel, and the grave was refilled. Archaeologists with the Commonwealth Heritage Group then traveled to West Point to excavate the rest of the coffin and skeleton. On Thursday, December 1<sup>st</sup>, 2016, I traveled to West Point to be present for the skeletal recovery and to do a preliminary assessment of the present remains. On the following day, skeletal recovery was completed, and the CID signed the remains out to me for analysis. I traveled back to Binghamton University where the remains were cleaned and analyzed.

## ANALYSIS RESULTS SUMMARY

<b>Number of Individuals</b>	One
<b>Age-at-Death</b>	45+ years
<b>Sex</b>	Male
<b>Ancestry</b>	Not determinable, but likely European or African based on context
<b>Stature</b>	Range of 5'7"-6'6"; Point estimate 6'
<b>Antemortem Conditions</b>	Severe dental disease, osteoarthritis in several locations, avulsion fracture of right humerus, possible fractured back, fractured right foot with secondary osteomyelitis. No conditions consistent with the injuries Margaret Corbin was known to have had.
<b>Distinguishing Features</b>	Pipe-stem groove on several teeth, several painful conditions, very robust and tall individual
<b>Postmortem Modifications</b>	Moderate-severe fragmentation due to coffin burial over time, sediment inclusion, and accidental construction damage; isolated copper and rust stains
<b>Time Since Death</b>	150+ years
<b>Presumptive Identification</b>	Not consistent with the remains of Margaret Corbin

## CONDITION OF REMAINS AND ANALYSIS CIRCUMSTANCES

The remains were cleaned and analyzed in the Bioarchaeology and Forensic Anthropology Laboratory at Binghamton University from December 4<sup>th</sup>-December 23<sup>rd</sup>, 2016. All remains were completely skeletonized and devoid of any soft tissue, including ligaments and cartilage, and were completely dry (non-greasy). Further, there was no evident odor of decomposition. No special preparation of the remains was needed prior to analysis, other than cleaning of adherent sediment with soft brushes and wooden tools. To facilitate analysis, fragments were pieced back together when possible, using water-based glue or wax.

Most of the bones are fragmentary and exhibit postmortem damage from the construction equipment and/or burial in a coffin and later sediment inclusion inside the decayed coffin. The skeleton is in fair condition, being approximately 85-90% complete. See Figures<sup>1</sup> 1 & 2.

## NUMBER OF INDIVIDUALS AND INVENTORY

One individual. While this skeleton is fragmentary, there was no duplication of any skeletal elements and all elements are consistent in terms of morphology, size, color, and age. This indicates that there is only one individual present.

---

<sup>1</sup> All figures are located in Appendix A, and technical terms are defined in the glossary following the bibliography.

Below follows a list of the hard tissues present and their condition. Almost all elements exhibited signs of postmortem damage. See Appendix B for the inventory diagram and images depicting fragments.

<b>Region</b>	<b>Elements Present</b>	<b>Condition</b>
<b>Skull</b>	Complete skull cap: parts of frontal, parietals, occipital	Mostly complete
	R temporal, frontal, occipital, L zygomatic, sphenoid, maxilla	Fragmentary
	Mandible	Mostly complete
	R and L maxillae	Mostly complete, although one other isolated smaller fragment present
	Several undetermined cranial fragments	Fragmentary (Figure B1)
<b>Dentition</b>	See dental chart (Appendix C)	Some postmortem damage but mostly complete
<b>Vertebral Column</b>	11 thoracic vertebrae	25-75% complete
	5 lumbar vertebrae	10%-95% complete
	Sacrum	Two small fragments
	Several vertebral fragments that could not be refitted	Fragmentary (Figure B1)
<b>Ribs and Sternum</b>	Manubrium	Mostly complete
	Sternal body	25% complete
	10 L ribs	50% complete
	4 R ribs	25% complete
	Several rib shaft fragments that could not be refitted	Fragmentary (Figure B1)
<b>Clavicles and Scapulae</b>	R and L clavicle	Mostly complete
	L scapula	50% complete
	R scapula	5% complete
<b>Upper Limb</b>	R and L humerus	Mostly complete
	R radius and ulna	Mostly complete
	L ulna	75% complete but fragmentary
	L radius	90% complete but fragmentary
<b>Hand and Wrist</b>	R & L trapezium	50%-100% complete
	R metacarpals 1-4	Mostly complete
	L metacarpals 4-5	Mostly complete
	9 proximal hand phalanges	Mostly complete (exception of 1)
	8 intermediate hand phalanges	Mostly complete
	2 distal hand phalanges	Mostly complete
<b>Innominate (pelvis)</b>	Right innominate	40% complete but fragmentary
	Left innominate	20% complete but fragmentary

	Several pelvic fragments that could not be refitted	Fragmentary (Figure B2)
<b>Lower Limb</b>	R & L femur; L patella	Mostly complete
	R & L tibia	90% complete, fragmented
	L fibula	15% complete
<b>Foot and Ankle</b>	R metatarsals 1-5	90-95% complete
	R 1 <sup>st</sup> & 3 <sup>rd</sup> cuneiform, talus, calcaneus	50-95% complete
	L talus	95% complete
	Fragments of navicular, cuboid (unside)	10% complete
	1 intermediate foot phalanx, 2 proximal foot phalanges	50% complete
<b>Other</b>	Several undetermined fragments, region unknown	Fragmentary (Figure B2)

## AGE-AT-DEATH

45+ years. There are several commonly-used methods for estimating age-at-death from skeletal remains. Unfortunately, the fragmentary nature of the skeleton in this case precluded the use of most of them. However, the method that utilizes the auricular surface of the ilium was still possible. The auricular surface is the location on the blade of the pelvis (ilium) where the sacrum (lower back) connects. Only the right auricular surface was present for analysis. Evaluation of the auricular surface using the Lovejoy et al. (1985) method resulted in a score of 7/8 on a 1-8 scale. This score corresponds to a range of 50+ years old at death.

Evaluation of tooth wear using the Brothwell (1981) and Miles (1962) methods resulted in age estimations of 35-42 years and 35-42 years, respectively.

Further, the upper and lower jaws were partially edentulous and the individual had many joint surfaces with changes indicative of mild-severe osteoarthritis (described in more detail below), not an uncommon finding for middle- to older-aged adults, yet rare in younger adults. In addition, the cranial sutures are about 75% obliterated, which suggests an older adult. See Figures 3-5.

As a result of the above analyses and results, this individual was 45+ years at death.

## ANCESTRY

Undeterminable. The most reliable and accepted methods to estimate ancestry rely on features of the skull, in particular the facial skeleton. Since the entire facial skeleton was fragmentary and/or not present, it was not possible to estimate ancestry for this individual. However, contextual evidence indicates that it is likely this individual was either of

European or African ancestry. See "time since death" section below for further discussion and explanation.

## **SEX**

Male. There are two major methods used to estimate sex: (1) morphoscopic examination of the pelvis and skull and (2) metric analysis of the cranial and postcranial skeleton.

The pelvis was in several fragments and several parts of it were absent. However, a few features were present that all indicated an estimate of male. Only part of the left pubis bone was present, but enough was there to determine that it was narrow (a female pubis is typically wide). The sciatic notch on the right fragmentary ilium was also relatively narrow, a typical male trait. See Figures 6-7.

While only part of the skull was present, four of the five features that are typically examined for sex estimation were present. All of these indicated a sex of male (i.e., a robust nuchal crest and mastoid process; rounded supraorbital margin, and square chin). Further, part of the browridge was present and it displayed marked development, a typical male trait. See Figures 8-10.

Measurements of the postcranial skeleton have recently been shown to be superior to metric or nonmetric sexing of the skull (Spradley and Jantz, 2011). Measurements of the postcranial skeleton work very well for assessing sex because humans are a sexually dimorphic species, meaning that males and females differ morphologically. In humans, this manifests itself by males being generally taller, larger, and more muscular than females. As a result, these differences play out in the long bones of the body, with bones of males generally being wider, longer, and more robust than the corresponding bones of females. Since this is the case, measurements of an unknown individual can be compared to a database of known sex individuals to assess sex.

There is population variation between American whites and blacks (European and African-Americans), meaning that differences exist with which postcranial measurements have the highest correct classification rates and what the sectioning points are (i.e., the measurement that is the cut-off between males and females) (Spradley and Jantz, 2011). Since it is not possible to reliably estimate ancestry for this case given the fragmentary skull, the measurements taken were compared to tables for both European and African-Americans.

Several postcranial measurements outlined in Spradley and Jantz (2011) were possible for this individual. Comparison of the measurements from this case and the published sectioning points revealed a classification of male for all of the measurements regardless of ancestry table used, with all measurements falling well above the published sectioning points (measurements falling below the sectioning points would indicate an estimate of

female). Note that the measurements reported all have classification rates of 80% or higher<sup>2</sup>. Refer to both tables, below.

### European-American Measurement Comparison

<b>Bone Measurement Name</b>	<b>Measurement in mm</b>	<b>*Sectioning Point</b>	<b>*Classification Rate</b>	<b>Sex</b>
Femur maximum head diameter	53 (left)	45	.88	M
Radius maximum length	260 (right)	241	.86	M
Humerus max length	365 (right)	320	.82	M
Humerus minimum diameter	22 (left)	17	.82	M
Ulna physiological length	250 (right)	229	.82	M
Femur bicondylar length	511 (left)	451	.82	M
Tibia circumference at nutrient foramen	105 (left)	92	.81	M
Femur maximum length	511 (left)	455	.80	M

\*Sectioning points and classification rates from Spradley and Jantz (2011).

### African-American Measurement Comparison

<b>Bone Measurement Name</b>	<b>Measurement in mm</b>	<b>*Sectioning Point</b>	<b>*Classification Rate</b>	<b>Sex</b>
Femur maximum head diameter	53 (left)	44	.86	M
Radius maximum length	260 (right)	253	.85	M
Femur Anterior-Posterior Subtrochanteric Diameter	33 (right)	27	.83	M
Ulna physiological length	250 (right)	240	.83	M
Femur bicondylar length	511 (right)	465	.81	M
Humerus maximum length	365 (right)	325	.81	M
Tibia diameter at nutrient foramen	38 (left)	35	.80	M

\*Sectioning points and classification rates from Spradley and Jantz (2011).

In addition to all of the above, the muscle markings on the bones were particularly prominent. Muscles attach to bones and the stronger a muscle is, the more robust the muscle attachment site on the bone will be. Every present muscle attachment site was evident, if not striking in its robusticity; including those that are typically hard to see (i.e, pectineal line on the femur), even on males. See Figure 11.

<sup>2</sup> Several other measurements also classified as male but the classification rates associated with those measurements are less than 80%, and therefore were omitted from this report for sake of clarity.



## STATURE

5'7"-6'6". All possible standard measurements of the postcranial skeleton were input into Fordisc 3.1 (Jantz and Ousley, 2005) and a multiple regression analysis using 19th century data (the closest available to the population this individual belonged to) was run which chose the best multivariate stature regression formula using a database of white males and black males. The formula chosen from the European American database with the highest R<sup>2</sup> value used the bicondylar length of the femur, the maximum length of the femur, and the maximum length of the radius. The point estimate was 6'.05", with a range of 5'8"-6'6". The formula chosen from the African American database with the highest R<sup>2</sup> value used the maximum length of the femur, the maximum length of the humerus, and the physiological length of the ulna. The point estimate was 6'.06", with a range of 5'7"-6'4". Both formulae were calculated using a 99% prediction interval. Therefore, this individual stood between 5'7" and 6'6" feet tall, and likely was closer to just over 6' tall.

## ANTEMORTEM CONDITIONS

Severe dental disease; mild-severe osteoarthritis in several locations; possible antemortem fracture of lower back secondary to osteoporosis; antemortem fracture of distal right humerus; antemortem fracture of right foot with secondary osteomyelitis.

### *Dental disease*

This individual had severe dental disease affecting every tooth. First, 13 of the 32 adult teeth were lost before death. This is typically due to dental caries (cavities) which over time will completely destroy a tooth. Often such teeth are extracted before they can decay completely away due to the pain involved (or in modern times a root canal may be performed). Two of the teeth (upper left canine and lower left second premolar) have only the root remaining following decay, and one of these (the canine) has an associated abscess, where the cavity infection in the tooth extended to the bone. One tooth (upper second premolar) has a developing cavity on its distal surface at the junction between the crown and the root. Further, the entire dentition suffered from severe periodontal disease. Periodontal disease is inflammation of the periodontal ligament, responsible for holding teeth in their sockets (Hillson, 1996). This inflammation causes the surrounding gums to recede, which then causes the bone to resorb. Over time, periodontal disease can become so severe that there is not enough bone left to keep the teeth secure. See Figures 4, 5, 9, 12, 13; and the appended dental chart (Appendix C).

In addition to the dental disease, the present teeth are severely worn. Some of this wear is related to age, but on the upper right 1<sup>st</sup> & 2<sup>nd</sup> premolar, upper right canine, and lower right canine & 1<sup>st</sup> premolar, this wear has a concave pattern consistent with a holding a pipe-stem between the teeth frequently. See Figure 14.

### *Osteoarthritis*

This individual suffered from extensive osteoarthritis at several joints in the body. Osteoarthritis (OA) is a common finding in middle-aged to elderly adults, as with time, the cartilage that cushions the joint surfaces breaks down, which eventually can result in bone

rubbing directly against bone (Mann and Hunt, 2012). An acute traumatic injury can also result in OA (Mann and Hunt, 2012). Both knee joints (femur, tibia) exhibit signs of OA, such as lipping around joint margins. The left proximal tibia (shinbone) has extensive osteophytic growths as well as eburnation on the lateral facet, where it articulates with the femur (thighbone). Eburnation is one of the final stages of OA, when no cushioning cartilage remains and bone is rubbing directly against bone. The left distal femur has postmortem damage so evaluation of eburnation on this corresponding element to the eburnated proximal tibia is impossible. See Figure 15.

The right elbow joint exhibits signs of severe OA. The proximal radius (one of the forearm bones) has porosity, pitting, lipping, and eburnation on its articulation with the humerus (upper arm bone), located along the posterolateral border. In addition, the ulna (elbow bone) has lipping and bone deposition inside the trochlear notch (where it attaches to the humerus). The humerus has some postmortem damage on its distal end so evaluation of eburnation and arthritis where the radius articulates is impossible, although it does have osteophytic growths inside the olecranon fossa, where the ulna articulates. See Figures 16-17.

The present bones of the spinal column (vertebrae) exhibit extensive osteoarthritis. None of the cervical vertebrae are present but 16 of the remaining 17 thoracic (T) and lumbar (L) vertebrae are, and while all exhibit postmortem damage, if at least one articular surface remains, it demonstrates signs of moderate-severe OA. Examples include lipping along body margins and moderate-severe porosity along articular facets for adjacent vertebrae or ribs. While the ribs are fragmentary, the present articular surfaces for the vertebrae demonstrate OA change as well. Beginning at the 5<sup>th</sup> thoracic vertebra (T5), there is severe porosity on the superior and inferior articular facets on the right side. This porosity continues in the same region on the same side through T8, with this anatomical region being absent postmortem on T9-T12. See Figures 18-20.

In addition, most of the present vertebrae exhibit Schmorl's nodes on either the superior or inferior side of the vertebral body (T5-9, L2, and L3). Schmorl's nodes are large pits in the vertebral body, and are a result of intervertebral disk herniation during life (Ortner, 2003). Disk herniation is supported by the presence of reactive, porous bone on the bodies of T6, T8, T9, T10, T11, L2, L3, L4, and L5. Further, T11 and T12 have severe bony changes (vertically-oriented growths, or syndesmophytes) on the anterior body surfaces which are consistent with the early stages of ankylosing spondylitis (AS). AS is an inflammatory disease with no known cause, but results in joint fusion. It affects males more frequently than females (Ortner, 2003). See Figures 20-24.

### ***Possible antemortem back fractures secondary to osteoporosis***

Osteoporosis is a disease affecting bone mineral density and is common in older adults as bone remodeling rates slow down (Ortner, 2003). Several vertebrae exhibit possible antemortem depression fractures as a result of osteoporosis. As the vertebral column is responsible for carrying the weight of the upper body, if bone mineral in the vertebral bodies is not sufficient, these bodies will eventually partially or completely collapse. The postmortem damage in this case made evaluation difficult, but the bodies of T7 and T11

exhibit misshapen bodies which could be due to an antemortem fracture. In addition, only a small fragment of the body of L4 was present, but this fragment demonstrates compression superiorly-inferiorly, supporting a depression fracture hypothesis. Further, the bone on the superior side of L5 is very reactive, which would be expected if a fracture had been present in the bone directly above it. See Figures 25-27.

### ***Humerus antemortem avulsion fracture***

The distal end of the right humerus (the area where it articulates to make the elbow joint) has morphological changes consistent with an avulsion injury of the medial epicondyle during childhood or early teenage years. The medial epicondyle is located on the medial side of the distal humerus, and is an attachment point for the common flexor tendon for several forearm flexor muscles (Netter, 1997). It appears between 4-6 years of age, and is fused in males between the ages of 14-16 (Scheuer and Black, 2000). There is postmortem damage including cortical erosion to the medial side of the distal humerus, making a definitive diagnosis difficult. However, the medial supracondylar line, which normally should arise above the medial epicondyle at a distinct angle, is absent. Avulsion fractures of muscle attachment sites are not uncommon in children while the different parts of their bones are still developing and fusing. An avulsion injury of the medial epicondyle before it fuses is most often caused by a severe pull on the attachment by the forearm flexor muscles, such as by throwing something over the head or from a fall onto an outstretched arm (Leahy et al., 2015). When this happens, it doesn't always reattach by itself. See Figures 28-29.

### ***Foot antemortem fracture and osteomyelitis***

The metatarsals corresponding to the 2<sup>nd</sup>-4<sup>th</sup> (and possibly 5<sup>th</sup>) digits of the right foot had an antemortem fracture. The metatarsals are located in the middle of the foot right before the toes. This fracture was located proximally and inferiorly, by the articulation with the tarsals, or ankle bones. It is possible that the fracture extended to the superior side but extensive postmortem damage of the superior side makes assessment impossible. The present tarsals are not affected. While there is some postmortem damage to the metatarsals, when all are articulated the path of the fracture is evident, as it partially displaced the proximal articular ends of at least the 2<sup>nd</sup>-4<sup>th</sup> metatarsals. Based on this evidence, it is likely that all four metatarsals were fractured during the same traumatic event. The fracture was healed and therefore had occurred at least several months to a few years before the individual died. See Figures 30-31.

In addition, the second right metatarsal had osteomyelitis secondary to the fracture. Osteomyelitis is an infection of the bone marrow and while it is a common condition following a fracture (especially in premodern times), it is also a very serious infection because it places infectious material in contact with the blood supply (Ortner, 2003). Evidence for osteomyelitis in this case is the presence of two cloacae, or holes, in the proximal end of the bone where infected material would have been draining. The rounded margins of these holes and smooth floors eliminates postmortem damage from consideration. The cloacae are located both on the posterior and lateral sides of the bone. See Figures 32-33.

### ***Summary of antemortem conditions***

The overall picture that therefore emerges is that of a middle-aged to older adult with severe dental disease, severe osteoarthritis likely causing pain in many of the major joints in the body, including the left knee, right elbow, and the entire thoracic and lumbar spine which included herniation of several intervertebral disks. In addition, this individual had likely suffered an avulsion fracture in the region of the right elbow as a child; had suffered a foot fracture as an adult which led to a serious bone infection; and possibly had suffered compression fractures of several vertebrae as an adult.

### **DISTINGUISHING FEATURES**

All of the conditions discussed above would have been distinguishing, especially the injuries as they would have likely caused the individual pain. The pipe stem groove on the right side of the jaws is also distinguishing although pipe smoking was a common habit in the past. Overall, the individual was tall and very muscular and likely would have stood out from his peers in this regard.

### **POSTMORTEM MODIFICATIONS**

The remains exhibit substantial cortical erosion, exfoliation, soil staining, and postmortem breakage. Some of the breakage is due to the actions of the construction equipment, and the rest is from gradual breakdown over time related to the wood coffin decay and eventual soil inclusion around the bones. Most of the construction-related damage is evident on the bones of the legs and the pelvis (Figures 1; 6 & 7).

The cranium has two areas of green staining (Figure 3). This is a common finding and is due to a metal object, likely made of copper, being in contact with the bone during decomposition. Such metal objects are typically part of the cultural materials (such as buttons on clothing or jewelry) that the decedent is buried with. In addition, the left femur has two areas of rust staining, likely due to being in contact with one or more coffin nails over time (Figure 34).

### **PRESUMPTIVE IDENTIFICATION**

These remains belonged to a male who was 45 years or older at his death and who was between 5'7" and 6'6" tall. He was a long time pipe smoker, who habitually held the pipe stem in the right side of his mouth and had suffered antemortem tooth loss of most molars and some premolars, as well as other teeth. He had periodontal disease and dental caries (cavities) leading to at least one abscess. He also had osteoarthritis on several joints, and had possibly suffered a fracture of the right humerus as a child, with a fracture of the right foot and subsequent infection occurring later as an adult. He had also possibly suffered from one or more compression fractures of the vertebrae.

The most compelling evidence that excludes Margaret Corbin from consideration is the fact that these remains did not belong to a female. In fact, the individual examined was a tall and very muscular male. The only corresponding feature to Margaret Corbin would be the

evidence of tooth wear indicating long time pipe smoking, as she was reported to have been a pipe smoker (Parker, 1926). However, none of the other features that would be expected of Margaret Corbin's remains are present – namely, injuries she was known to have suffered during the Battle of Fort Washington on November 16, 1776 to her shoulder and breast (Parker, 1926). These grapeshot injuries are known to have been debilitating to her for years and resulted in the loss of use of one arm (Parker, 1926), and as a result it is highly unlikely that they were confined to the soft tissues alone (i.e., bone involvement would be expected). Such bone involvement would be evident upon skeletal analysis, and would likely include healed fracture(s), bone remodeling, atrophy, infection, and/or embedded lead fragments in the proximal humerus, scapula, and/or clavicle.

The historical record does not indicate which side of the body was injured. While the left scapula is only about 50% complete and only a small fragment of the right one is present, both humeri (upper arms) are about 99% complete and neither demonstrates signs of ballistic injury; and the present parts of the scapulae are uninjured. Neither clavicle, which comprises the third bone<sup>3</sup> of the shoulder joint, demonstrates signs of injury. The present parts of the breastbone (manubrium and part of sternal body) do not demonstrate signs of injury, only osteoarthritis. Unfortunately, the sternal ends of the ribs are either absent or mostly fragmentary due to postmortem effects and so the evaluation of whether there was an antemortem injury in the pectoral region is impossible. See Figures 1; 35-39.

The grave located by the Daughters of the American Revolution (DAR) in 1926 on J.P. Morgan's 700-acre estate (Cragston) in Highland Falls, New York belonged to someone else, and not to Margaret Corbin. The search of historical records led the DAR to a particular location on the Morgan estate (Parker, 1926). However, a stump of a cedar tree and not a headstone indicated the grave's location. This was used to corroborate the historical record indicating that a cedar tree had been planted next to Corbin's grave (Parker, 1926). Parker (1926) notes that two or three other graves were on the estate. It is unclear exactly where these other graves were located, although Parker (1926) notes that at the time of the DAR investigation, there was an unbroken chain of individuals with knowledge of where the grave was located extending back to the undertaker who had dug Corbin's grave (i.e., the undertaker showed his son the grave, who later showed it to several other people). If this witness information is to be believed, it then stands to reason that all the graves were in the same general vicinity, making the error more likely.

Following exhumation, the DAR opened the coffin and consulted with the West Point surgeon regarding the state of the remains. He determined that the skeleton was that of a female and that there were injuries on the left shoulder consistent with the historical record indicating Margaret Corbin had been shot in the shoulder (Parker, 1926). Further, Parker (1926) indicates that only bones and no personal effects, such as clothing remnants, were present; and that the coffin had completely decayed away.

---

<sup>3</sup> The shoulder joint is comprised of the proximal (top half) humerus, scapula, and clavicle

In 1926, human skeletal analysis and specifically physical anthropology<sup>4</sup> was a nascent field, practiced only by a handful of practitioners (less than 10), mostly anatomists at museums and medical schools (Tersigni-Tarrant and Shirley, 2013). Unless the consulted physician was one of these practitioners and/or was a specialist in orthopedics or bone trauma, it is unlikely that he had knowledge of how to tell male from female bones and what trauma to the skeleton looks like. The left shoulder has damage consistent with a postmortem environment (i.e., long time coffin burial and eventual soil inclusion), and so it is likely that the physician confused antemortem trauma with postmortem damage (Figures 35-38).

---

<sup>4</sup> The first practitioner recognized as doing bone skeletal analysis for purposes of identification was working at Harvard in the mid-late 1800s. By 1920, the major institutions where skeletal analysis for purposes of identification was being practiced, researched, and/or taught were the Smithsonian Institution, Harvard, the Field Museum in Chicago, and Case Western Reserve University. Forensic anthropology was born out of physical anthropology, which includes skeletal analysis, and was not named formally as such until the late 1970s.

## TIME SINCE DEATH

150+ years. The skeleton is completely devoid of soft tissue and odor in addition to being very dry (i.e., non-greasy); and was found in a cemetery context. Further, the skeleton was found with associated nails, wood, and coffin hardware, indicating a coffin burial. Given the evidence presented here that these remains are not those of Margaret Corbin, a major question remaining is who this individual may be. If the third hypothesis presented above is true, then we know that the remains analyzed here were exhumed in 1926 by the DAR and at that time were completely skeletal, devoid of all soft tissue, with no clothing remaining (Parker, 1926). The apparent lack of cultural materials (such as shell beads, glass beads, or metal artifacts, all of which would not have decayed away) suggests non-native ancestry (Versaggi, pers. comm., 2016).

Along with the absent burial marker, the condition of the remains during the first exhumation indicates that the individual had already been in the ground for several decades by 1926. A conservative estimate would be *at least* five decades before the initial exhumation, although it is likely substantially longer, given the complete coffin and clothing decay. This would place the individual as being alive at some point from the colonial period through the early – mid 19<sup>th</sup> century.

## SUMMARY

To summarize, the anthropological analysis indicates that these remains are not those of Margaret Corbin. Rather, they represent those of a tall, muscular, middle-aged to older male experiencing several health problems, alive at some point between the colonial period and the 19<sup>th</sup> century.

## REFERENCES CITED

Brothwell, DR (1981). *Digging Up Bones*, 3<sup>rd</sup> edition. London & Oxford, British Museum and Oxford University Press.

Hillson, S (1996). *Dental Anthropology*. Cambridge, Cambridge University Press.

Leahy, I, Schorpion, M, and T Ganley (2015). Common medial elbow injuries in the adolescent athlete. *Journal of Hand Therapy* 28: 201-211.

Lovejoy, CO, Meindl, RS, Pryzbeck, TR, & RP Mensforth (1985). Chronological metamorphosis of the auricular surface of the ilium: a new method for the determination of age at death. *American Journal of Physical Anthropology* 68: 15-28.

Mann, RW and DR Hunt (2012). *Photographic Regional Atlas of Bone Disease*, 3<sup>rd</sup> edition. Springfield, Charles C. Thomas.

Miles, AEW (1962). Assessment of the ages of a population of Anglo-Saxons from their dentitions. *Proceedings of the Royal Society of Medicine* 55: 881-886.

Nelson, P (1925). Letter to Mrs. Alton B. Parker dated December 15, 1925 from Peter Nelson, Public Records Section of the The University of the State of New York, The State Department of Education, Albany.

Netter, F (1997). *Atlas of Human Anatomy*, 2<sup>nd</sup> edition. ICON Learning Systems.

Ortner, D (2003). *Identification of Pathological Conditions in Human Skeletal Remains*. San Diego, Academic Press.

Ousley, SD and RL Jantz (2005). *Fordisc 3.1: Personal Computer Discriminant Functions*. Knoxville, The University of Tennessee.

Parker, AC (1926). Revolutionary heroine interred in West Point Cemetery. *Daughters of the American Revolution Magazine*. June 1926. pgs. 347-352.

Scheuer, L and S Black (2000). *Developmental Juvenile Osteology*. London, Academic Press.

Spradley, MK & RL Jantz (2011). Sex estimation in forensic anthropology: skull versus postcranial elements. *Journal of Forensic Sciences* 56(2): 289-296.

Tersigni-Tarrant, MA & NR Shirley (2013). *Forensic Anthropology: An Introduction*. Boca Raton, FL, CRC Press.

Versaggi, N (2016). Director of Public Archaeology Facility, Binghamton University. Personal communication regarding typical Native American burial styles and inclusions. December 23, 2016.

## **GLOSSARY**

Abscess: hole in *alveolar bone* caused by infection that begins as a cavity in a tooth.

Alveolar bone: the bone of the jaws that surrounds the teeth.

Ankylosing spondylitis: an inflammatory disease with no known cause, but results in joint fusion. It affects males more frequently than females.

Antemortem: before death.

Anterior: anatomical position term; towards the front of the body. Its opposite term is *posterior*.

Avulsion fracture: a *fracture* that results in the removal of part of a bone.

Caries: tooth cavity.



Cementoenamel junction: anatomical area on a tooth that separates the root of the tooth from the crown of the tooth.

Distal: anatomical position term that applies to the upper and lower limbs of the body - means further away from that limb's point of attachment to the torso. For example: The fingers are distal to the elbow. Its opposite is *proximal*.

Eburnation: shiny bone joint surface caused by bone rubbing on bone due to the loss of cushioning joint cartilage. Is one of the final stages of *osteoarthritis*.

Fracture: break in a bone.

Inferior: anatomical position term; towards the feet of the body. Its opposite term is *superior*.

Lateral: anatomical position term; towards the sides of the body. Its opposite term is *medial*.

Medial: anatomical position term; towards the midline of the body (i.e., the breastbone is located in the exact midline). Its opposite term is *lateral*.

Osteoarthritis: disease of the joints caused by breakdown of the cartilage that cushions the joint surfaces. This can eventually result in bone rubbing directly against bone, and it causes several characteristic findings, such as *porosity*, *reactive bone*, *eburnation*, and/or *osteophytes*.

Osteomyelitis: an infection of the bone marrow; a common condition following a fracture (especially in premodern times before antibiotic therapy). It is a very serious infection because it places infectious material in contact with the blood supply (Ortner, 2003).

Osteoporosis: a disease affecting bone mineral density, so that there is less than ideal mineral content in the bones. It is common in older adults as bone remodeling rates slow down (Ortner, 2003).

Osteophytes/osteophytic growths: abnormal bone growths that are often the result of a pathology such as osteoarthritis or trauma.

Periodontal disease: inflammation of the periodontal ligament, responsible for holding teeth in their sockets (Hillson, 1996). This inflammation causes the surrounding gums to recede, which then causes the bone to resorb. Over time, periodontal disease can become so severe that there is not enough bone left to keep the teeth secure.

Porosity/porous bone: bone that has a moth-eaten or Swiss cheese-like appearance due to some pathological or traumatic process.

Posterior: anatomical position term; towards the back of the body. Its opposite term is *anterior*.

Postmortem: after death.

Proximal: anatomical position term that applies to the upper and lower limbs of the body – means closer to that limb's point of attachment to the torso. For example: The shoulder is proximal to the elbow. Its opposite term is *distal*.

Reactive bone: See *Porosity/porous bone*.


Schmorl's nodes: large abnormal pits in the vertebral body, occur as a result of intervertebral disk herniation during life (Ortner, 2003).

Superior: anatomical position term; closer to the top of the head. Its opposite term is *inferior*.

Syndesmophytes: vertically-oriented growths located on bones, consistent with the pathological condition *ankylosing spondylitis*.

Trabecular bone: a type of normal bone tissue; it is located on the inside of several bones in many different places depending on which bone it is.

Respectfully completed and submitted on this 26<sup>th</sup> day of January, 2017.



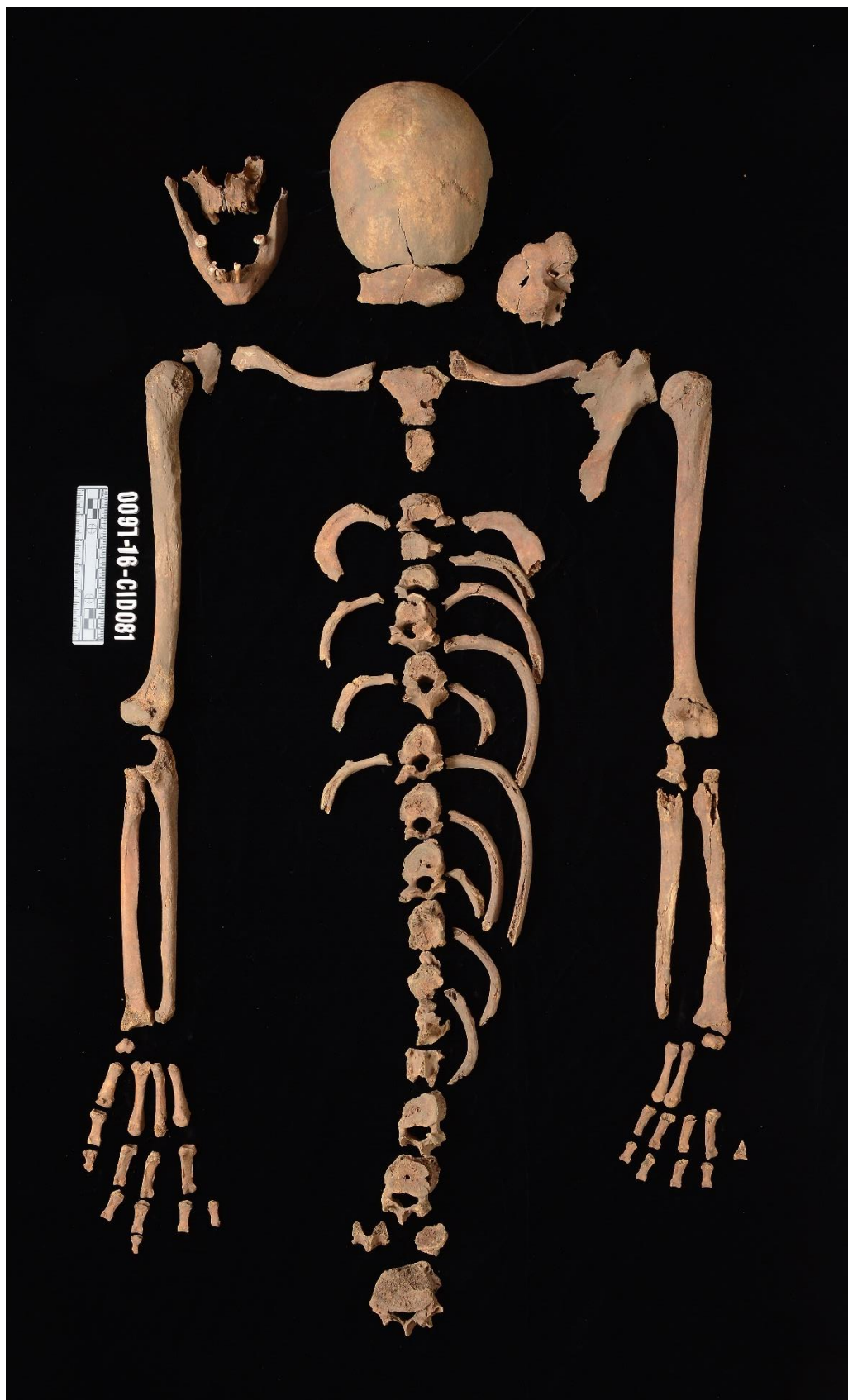Elizabeth A. DiGangi, PhD, D-ABFA  
Assistant Professor  
Department of Anthropology  
Binghamton University

**Figure 1.**

Superior half of skeleton, anatomical position. Anterior view. Smaller fragments omitted for clarity.

Right

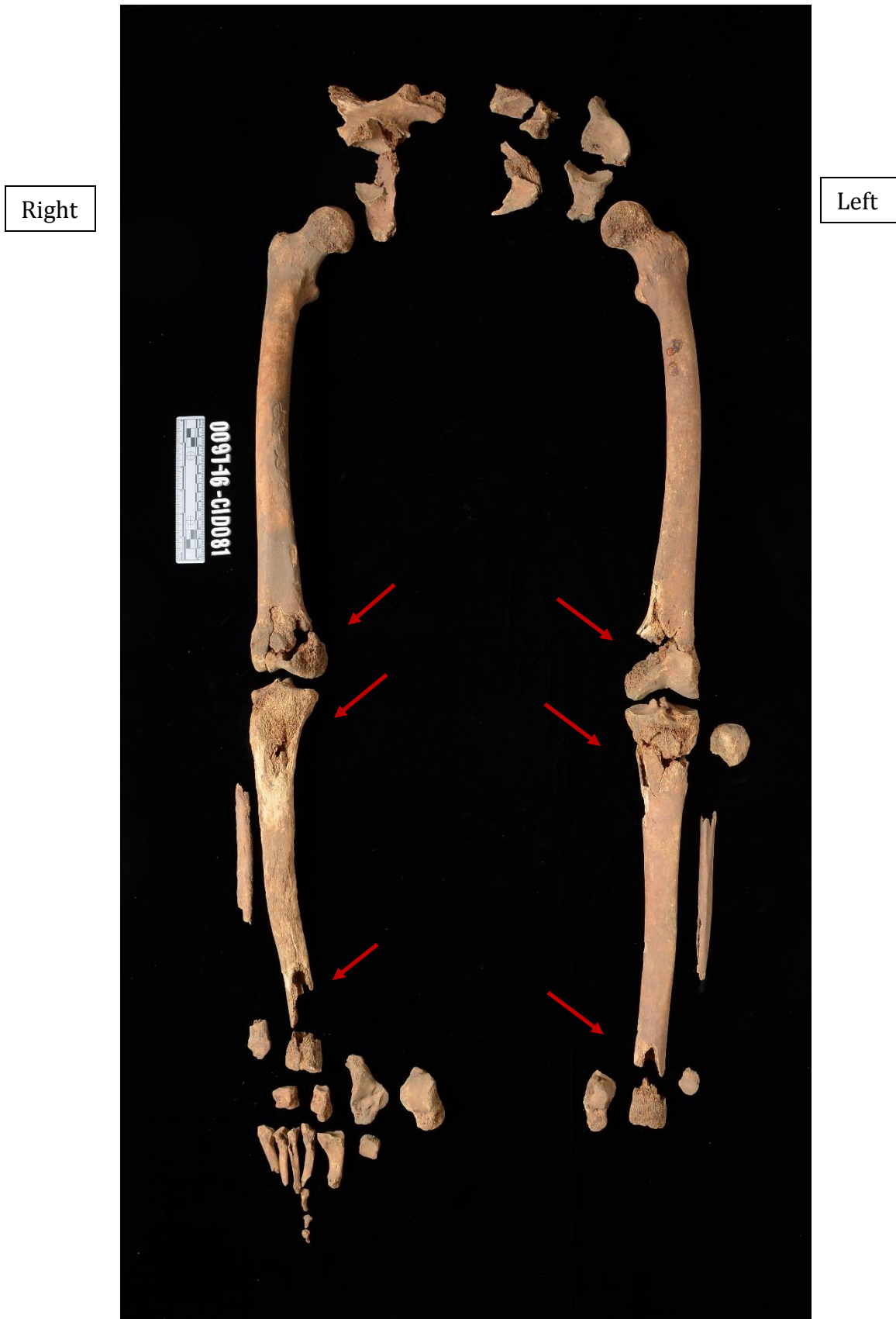
Left





**Figure 2.**

Inferior half skeleton, anatomical position. Anterior view. Smaller fragments omitted for clarity. Arrows denote some of the postmortem damage.





**Figure 3.**

Superior view of cranium. Anterior (forehead) is to left. Note partially obliterated coronal suture (green arrow), completely obliterated sagittal suture (yellow arrows); and two areas of copper staining (red arrows). Fractures on frontal bone are postmortem. Discussion on page 4 of report.

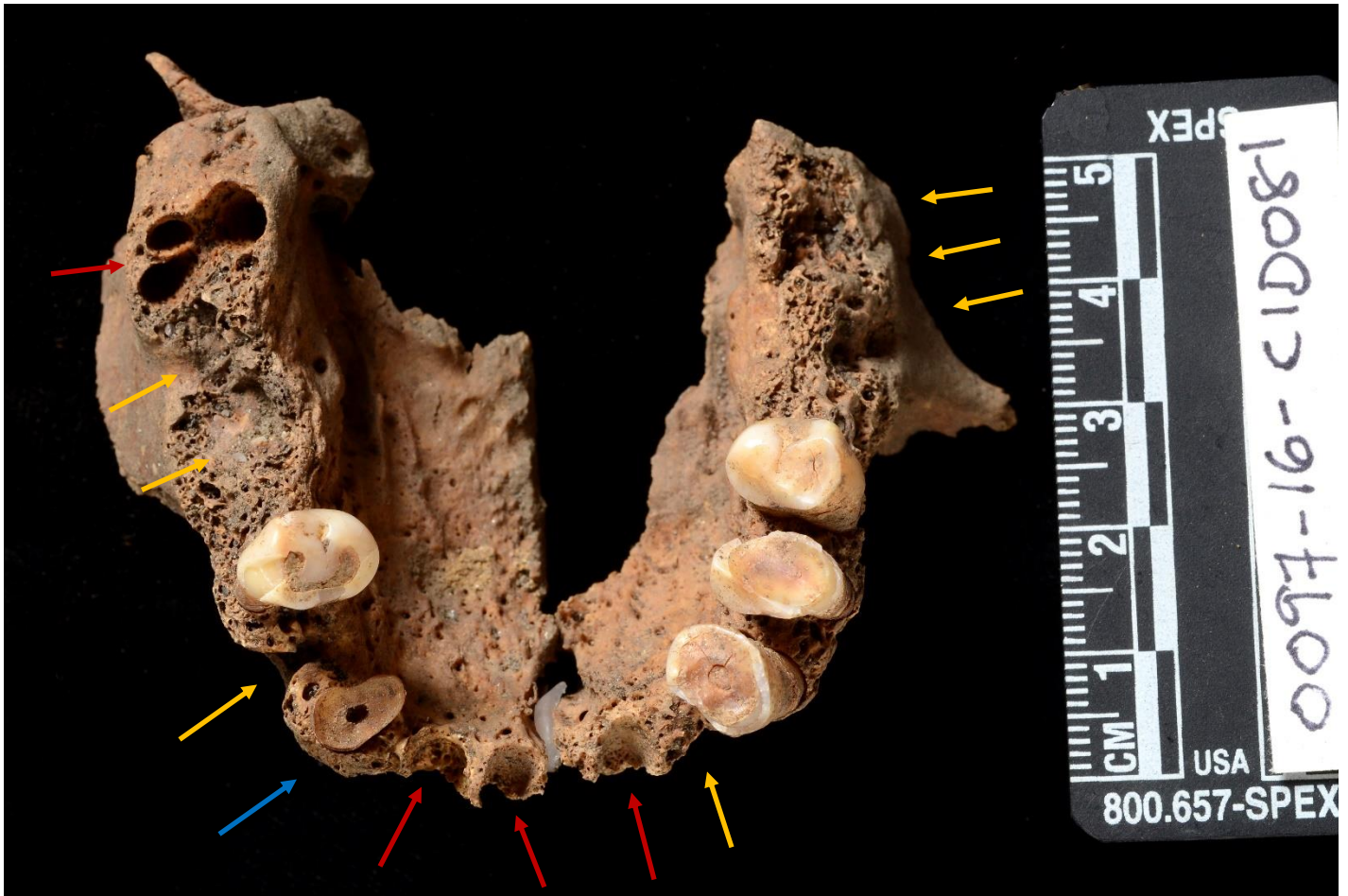





**Figure 4.**

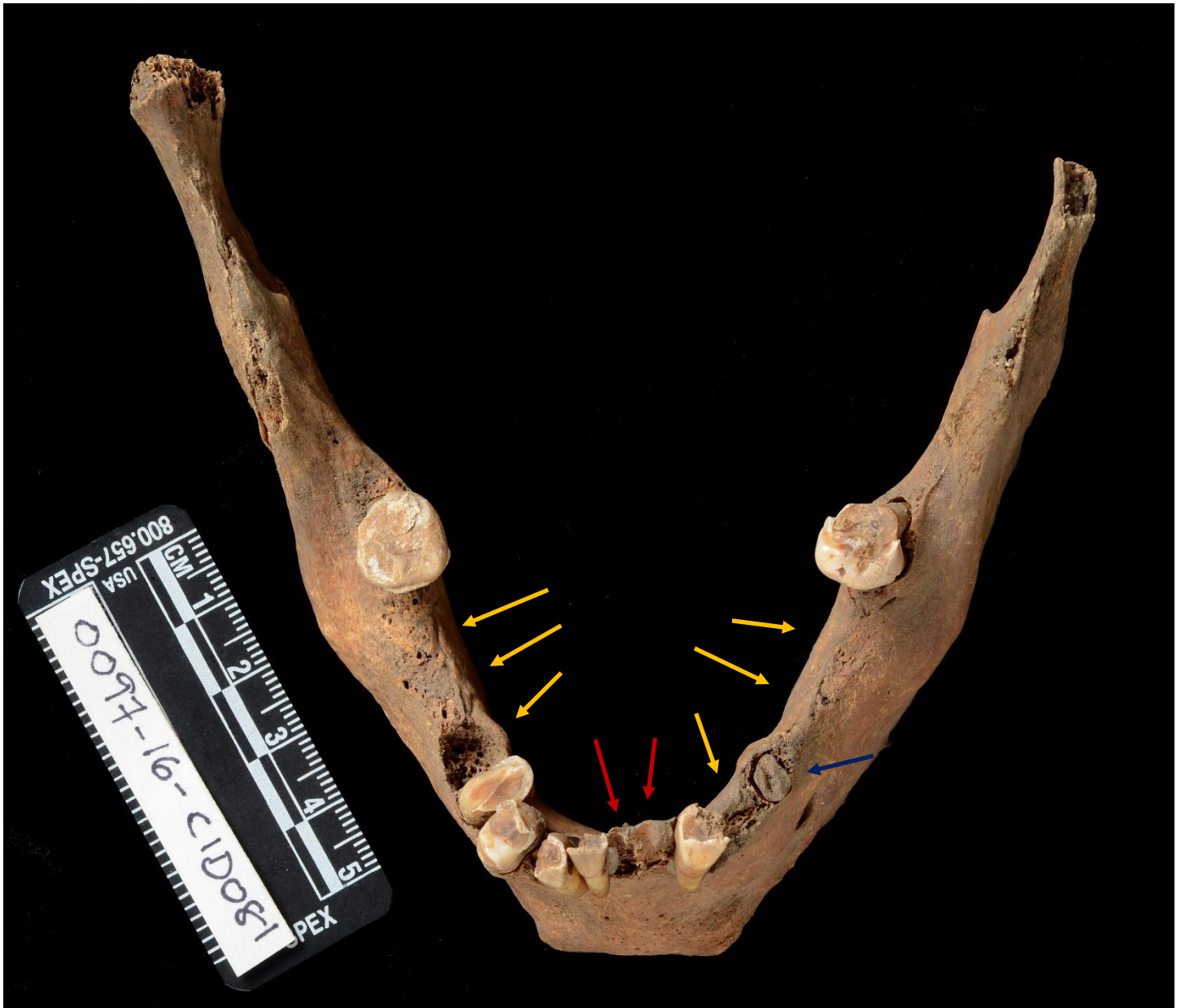Inferior side of maxilla. Note antemortem loss (yellow arrows) and wear. Red arrows denote postmortem loss. Blue arrow denotes decaying left canine. (Dental wax is being used to hold the two halves together in the middle). Discussion on page 4 of report.





**Figure 5.**

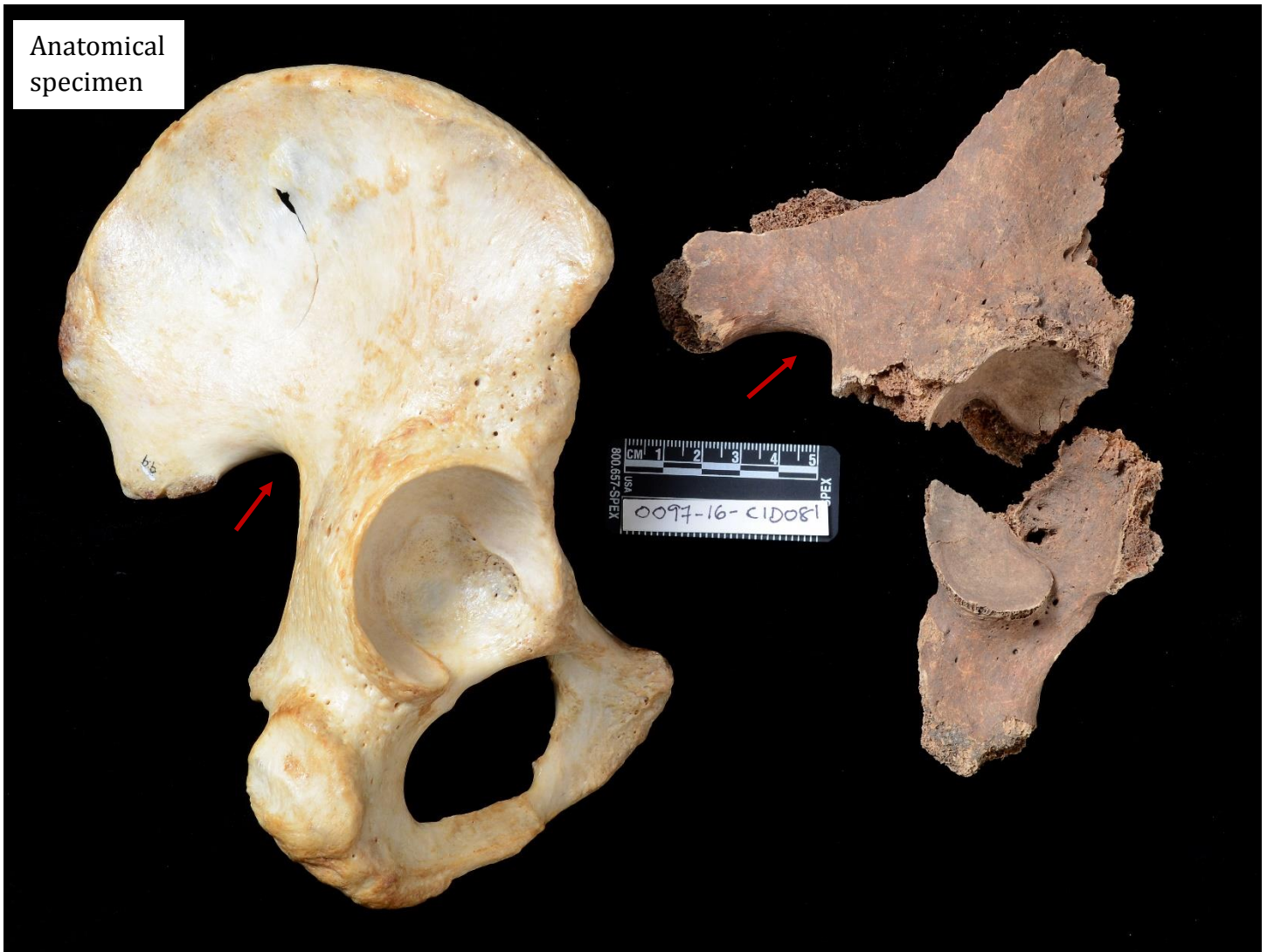Superior view of mandible. Note antemortem loss (yellow arrows) and wear. Red arrows denote postmortem loss. Blue arrow denotes decaying left 2<sup>nd</sup> premolar. Discussion on page 4 of report.





**Figure 6.**

Right side fragmentary pelvis on right of image, posterolateral view. Complete anatomical specimen of male individual shown on left for comparison. Same anatomical view depicted. Sciatic notch indicated on both specimens. Discussion on page 5 of report.

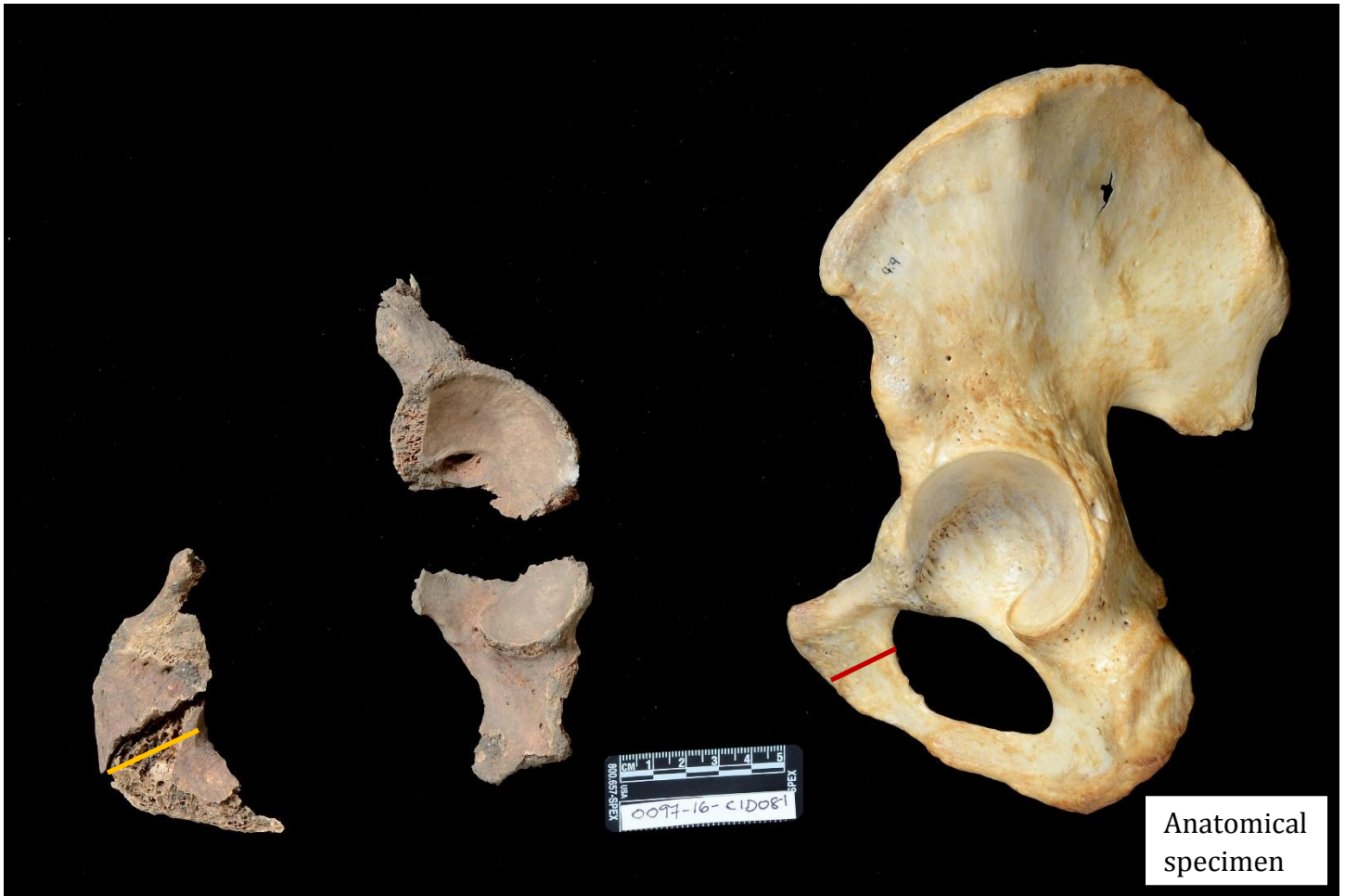





**Figure 7.**

Left side fragmentary pelvis on left side of image, posterolateral view. Complete anatomical specimen of male individual shown on right for comparison. Same anatomical view depicted. The width of the pubis bone is indicated on both specimens. (A female pubis is typically close to twice the width observed here). Discussion on page 5 of report.







**Figure 8.**

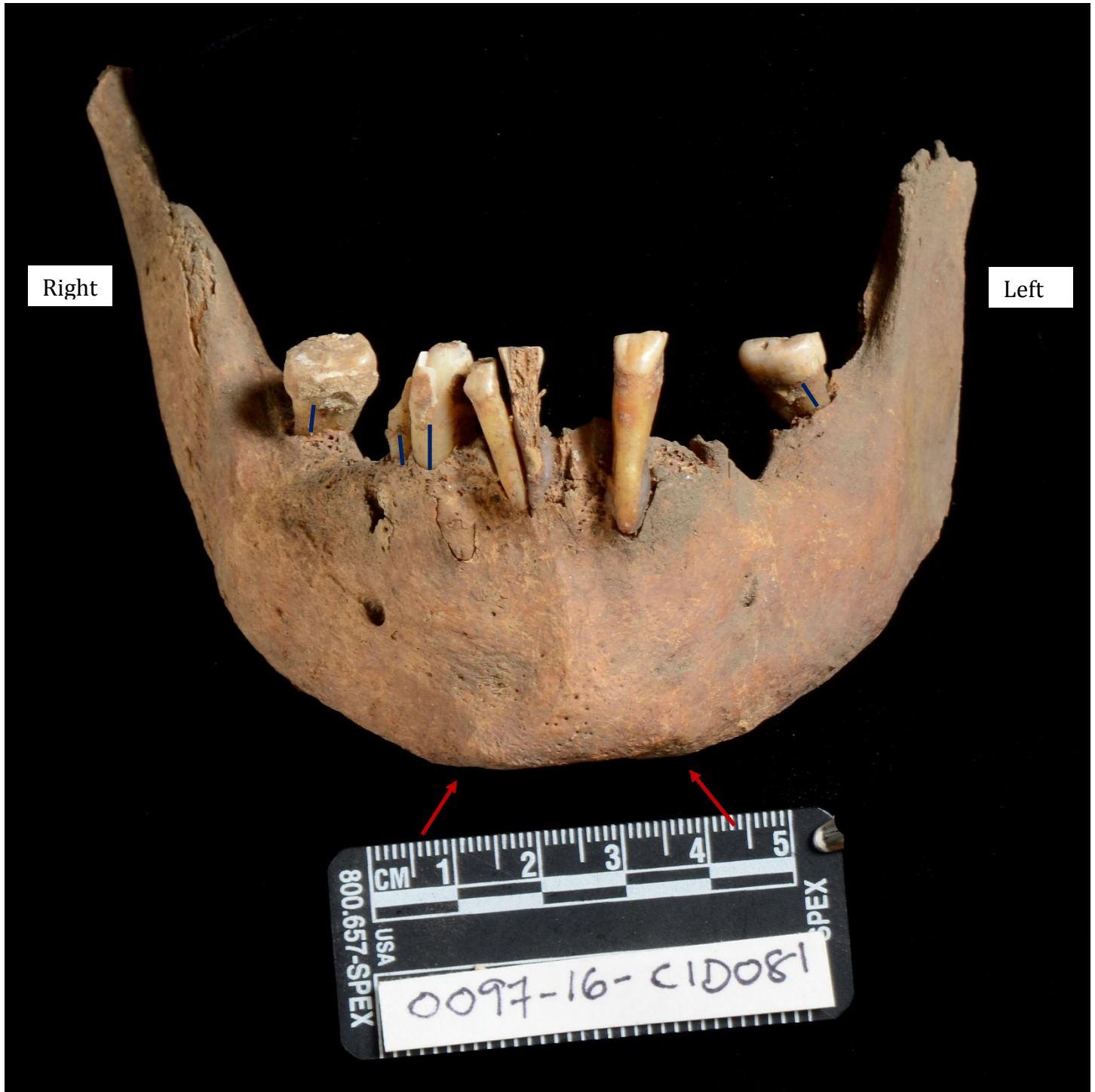Posterior view of cranium. Red arrows denote robust nuchal crest. Also note partially obliterated lambdoid and sagittal sutures (yellow arrows). Discussion on page 5 of report.





**Figure 9.**

Anterior view of mandible. Note square mental eminence (chin) – red arrows; and substantial periodontal disease, as well as tooth loss. The alveolar bone is supposed to reach up to the junction between the crown and the root. Here, it is evident that quite a bit of space is present. Note blue lines. (The alveolar bone on the anterior teeth has been damaged postmortem and thus alveolar recession is evaluated on the right canine, right 1<sup>st</sup> premolar, and two present molars). The anterior teeth are being held in their sockets by dental wax. Discussion on page 5 of report.





**Figure 10.**

Frontal (forehead) fragment, anterior. Red arrows indicate well-developed browridge. Green arrow denotes rounded supraorbital margin. The middle of the forehead (with postmortem breakage revealing the frontal sinus cavity) is denoted with a yellow arrow. The fractures that run down the middle are postmortem. Discussion on page 5 of report.

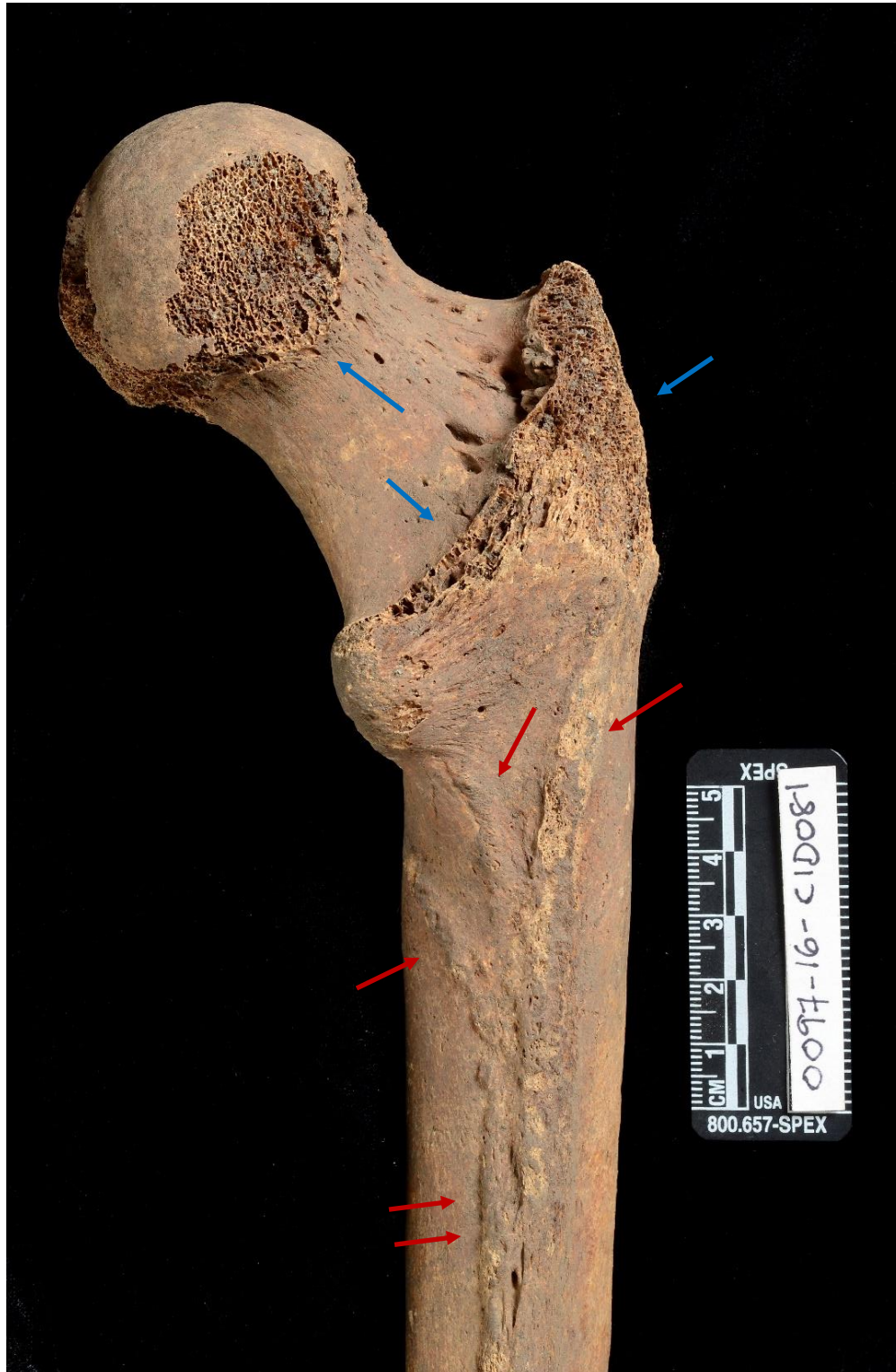





**Figure 11.**

Posterior side of proximal right femur. Note postmortem damage (coffin wear) - blue arrows. Red arrows depict robust muscle marking lines. From left of image to right: spiral line, pectineal line, gluteal tuberosity. Double arrows in middle of shaft (bottom of image) indicate robust linea aspera, attachment site for several leg and hip muscles. Discussion on page 6 of report.







**Figure 12.**

Anterior view of maxilla. Note abscessed left canine (red arrow). Postmortem tooth loss indicated by red arrows. Discussion on page 7 of report.





**Figure 13.**

Upper right second premolar, cavity at junction between the crown and the root (cementoenamel junction). Distal view (view from posterior). Discussion on page 7 of report.

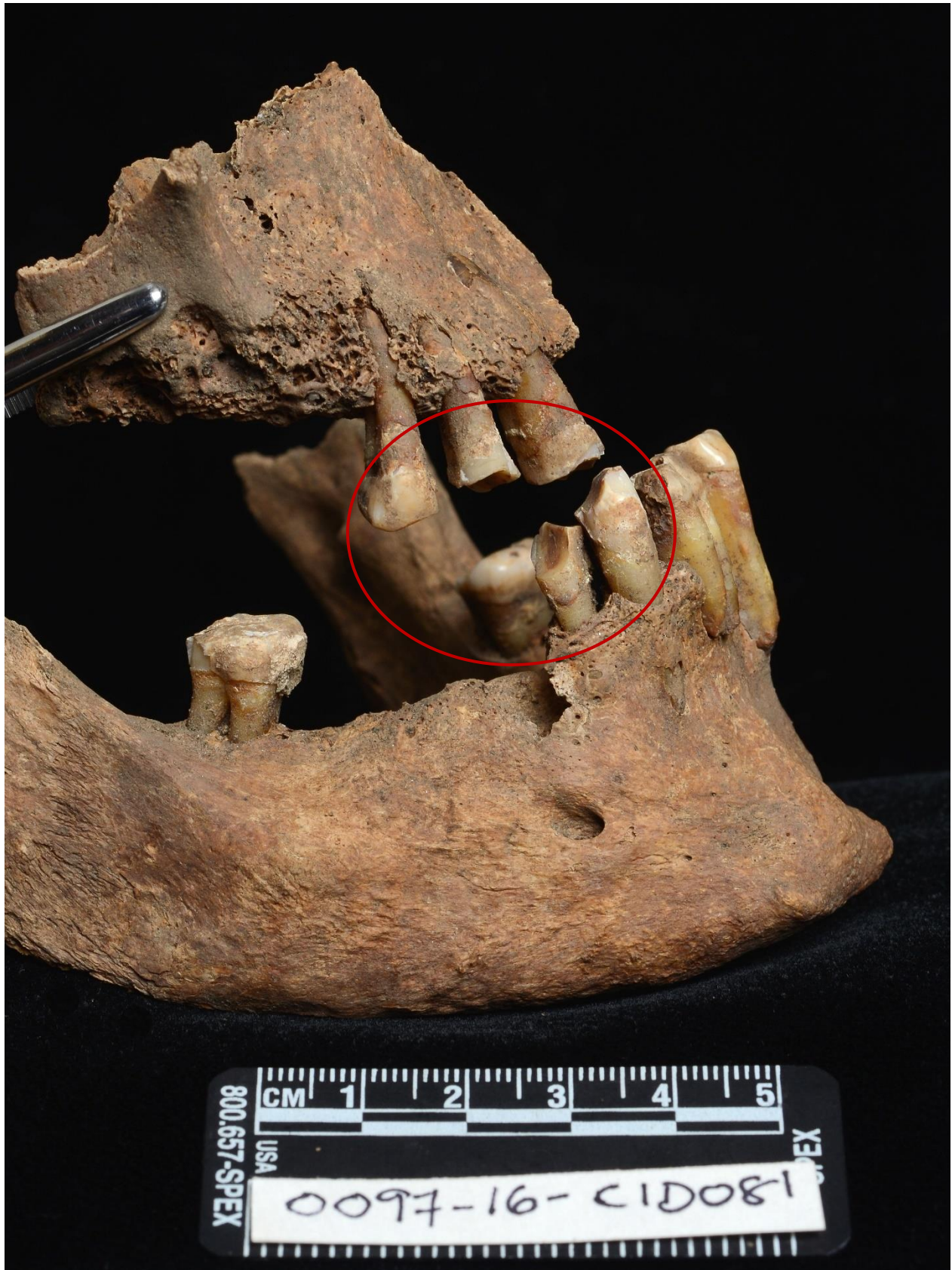





**Figure 14.**

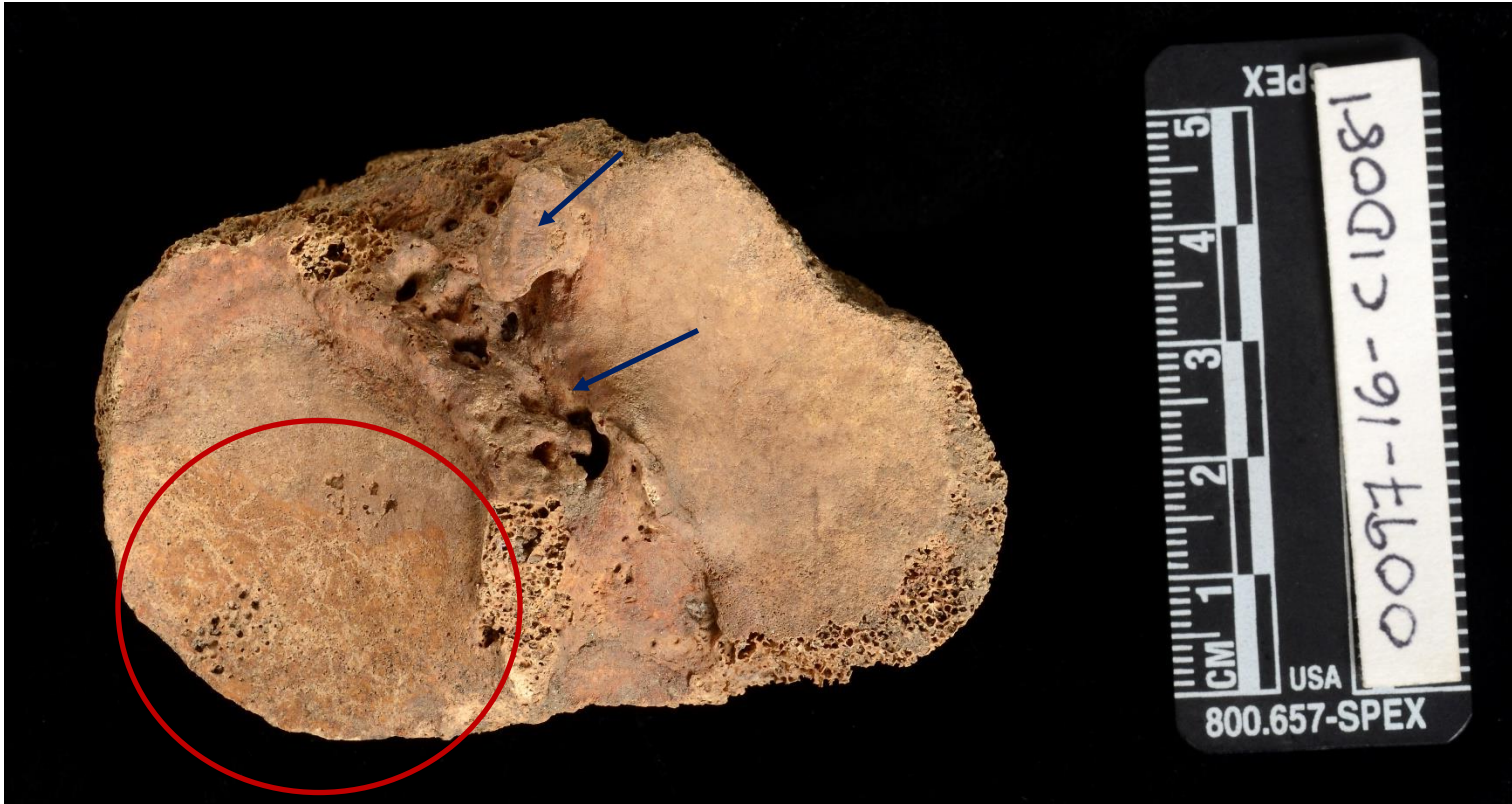Right side of jaws in approximate occlusion. Note concave wear pattern on the upper canine, 1<sup>st</sup> & 2<sup>nd</sup> premolars, lower canine, and 1<sup>st</sup> premolar, consistent with a pipestem. Discussion on page 7 of report.





**Figure 15.**

Eburnation (shiny area, red circle), left proximal tibia. Reactive bone consistent with osteoarthritis present in intercondylar eminence region, blue arrows. Anterior to top, lateral facet on left. Discussion on page 8 of report.







**Figure 16.**

Right proximal radius (head). Posterior to top image, lateral to right. Note porous bone on entire surface and eburnation, consistent with osteoarthritis (shiny area, red arrows). Discussion on page 8 of report.





**Figure 17.**


Distal end of right humerus, posterior, medial to left. Note osteophytic growths consistent with osteoarthritis inside olecranon fossa (where ulna articulates), red arrows. Discussion on page 8 of report.





**Figure 18.**

Thoracic vertebrae, T1-T12 (T2 absent postmortem). Anterior. Note postmortem damage (less smooth or fractured areas, with exposed trabecular bone) and osteophytic growths, also known as lipping, consistent with osteoarthritis (some noted with red arrows). Blue arrows denote syndesmophytes, consistent with ankylosing spondylitis (see Figures 23 & 24 for description). Discussion on page 8 of report.







**Figure 19.**

Thoracic vertebra #5, posterior view. Note porosity associated with osteoarthritis on right superior articular facet. Fracture on left articular facet is postmortem. Discussion on page 8 of report.







**Figure 20.**

Thoracic vertebra #5, inferior view. Note osteoarthritic porosity on right inferior articular facet (red arrow) as well as substantial Schmorl's node on inferior side of body (blue arrows). Fracture that runs through the body is postmortem. Discussion on page 8 of report.





**Figure 21.**

Thoracic vertebra #9, inferior view. Note Schmorl's node (red arrow) as well as porous and reactive bone (blue arrows). Discussion on page 8 of report.

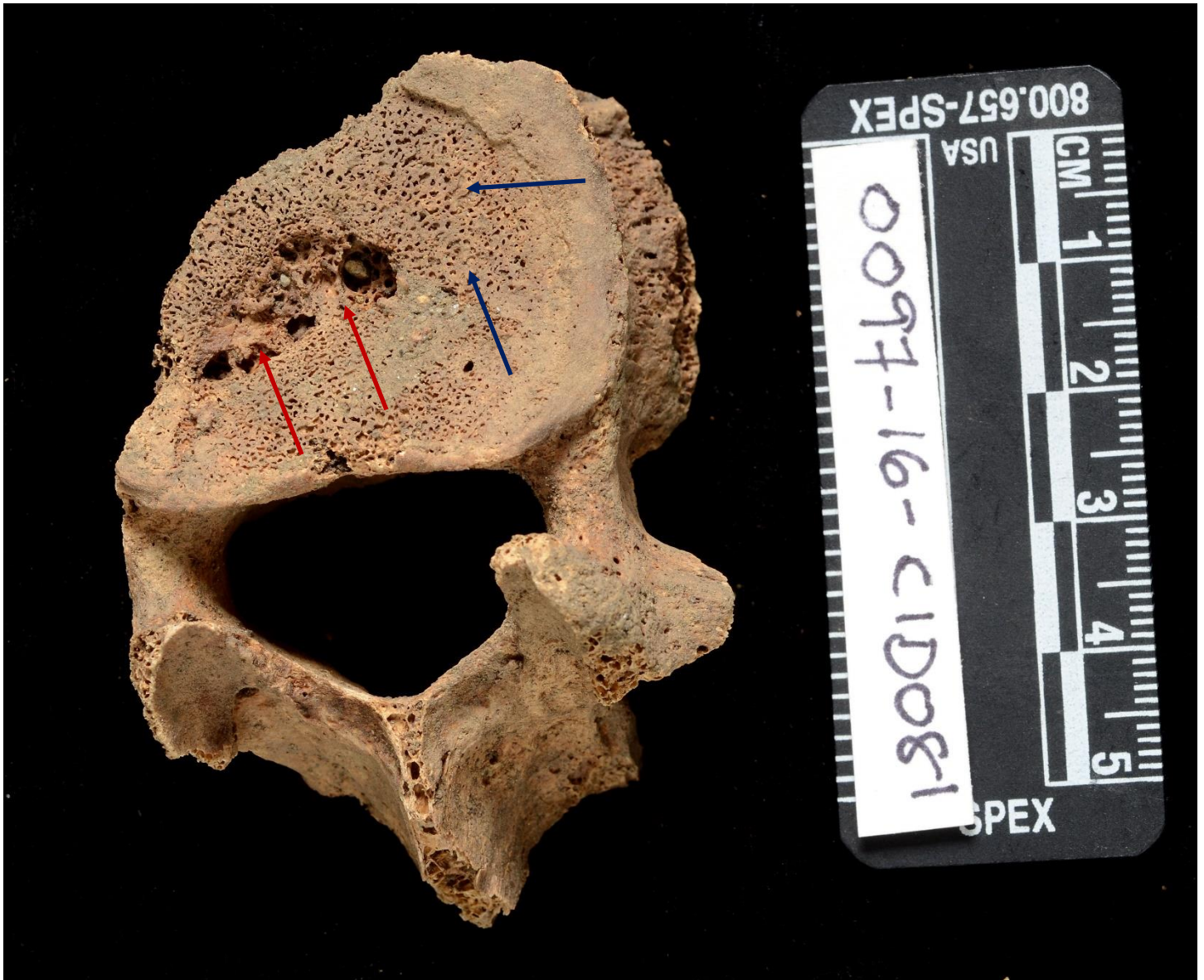





**Figure 22.**

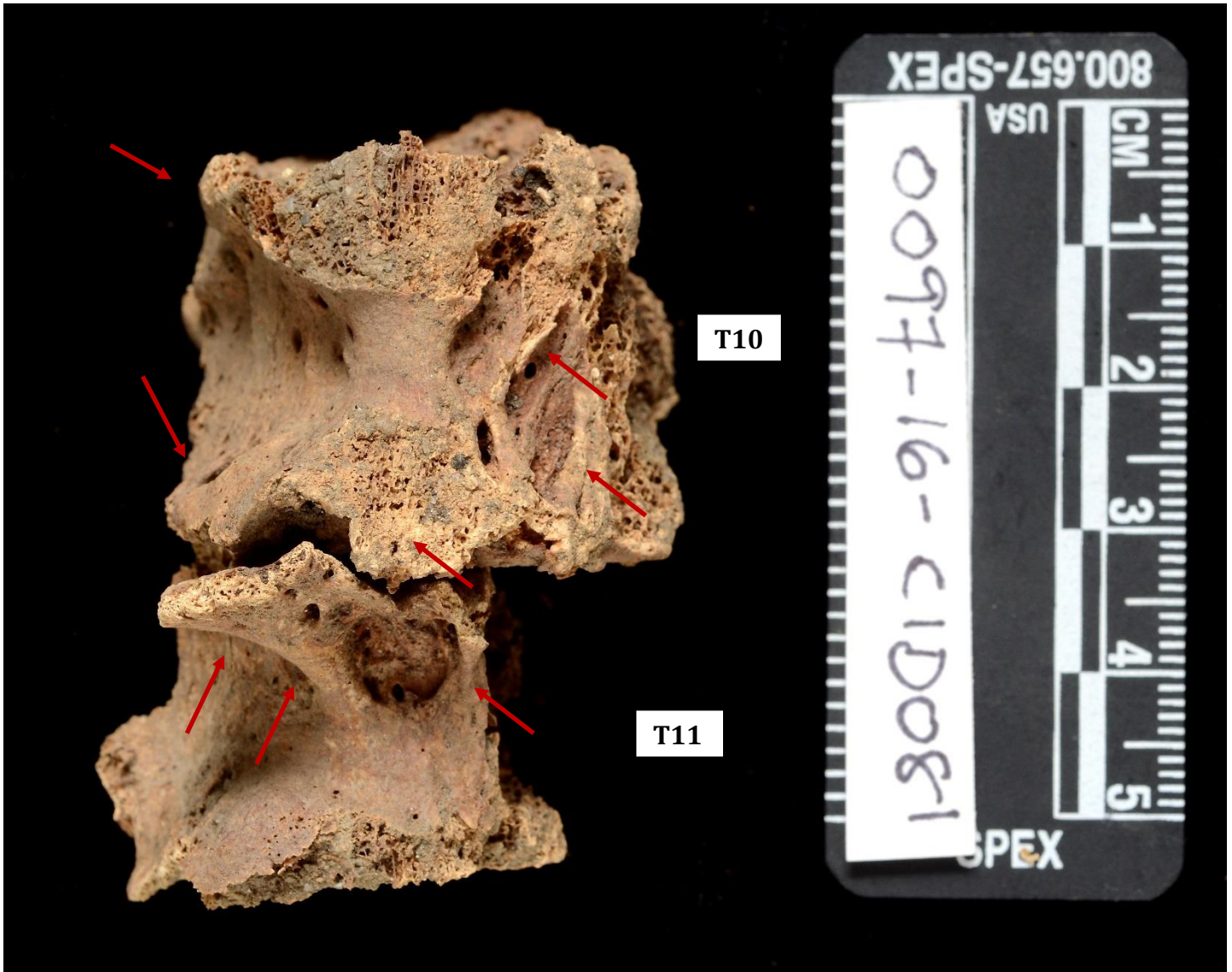Lumbar vertebra #2, superior. Note Schmorl's node (red arrows) as well as porous and reactive bone (blue arrows). Discussion on page 8 of report.





**Figure 23.**

Thoracic vertebrae #10 & 11, articulated. Anterior view. Note severe bony changes (syndesmophytes) – red arrows - possibly indicating ankylosing spondylitis. See page 8 of report for definition and discussion.







**Figure 24.**

Thoracic vertebrae #10 & 11, articulated. Right side, anterior to right side of image. (Postmortem damage has removed the spinous processes on the posterior side). Note severe bony changes (syndesmophytes) - red arrows - possibly indicating ankylosing spondylitis. Discussion on page 8 of report.





**Figure 25.**

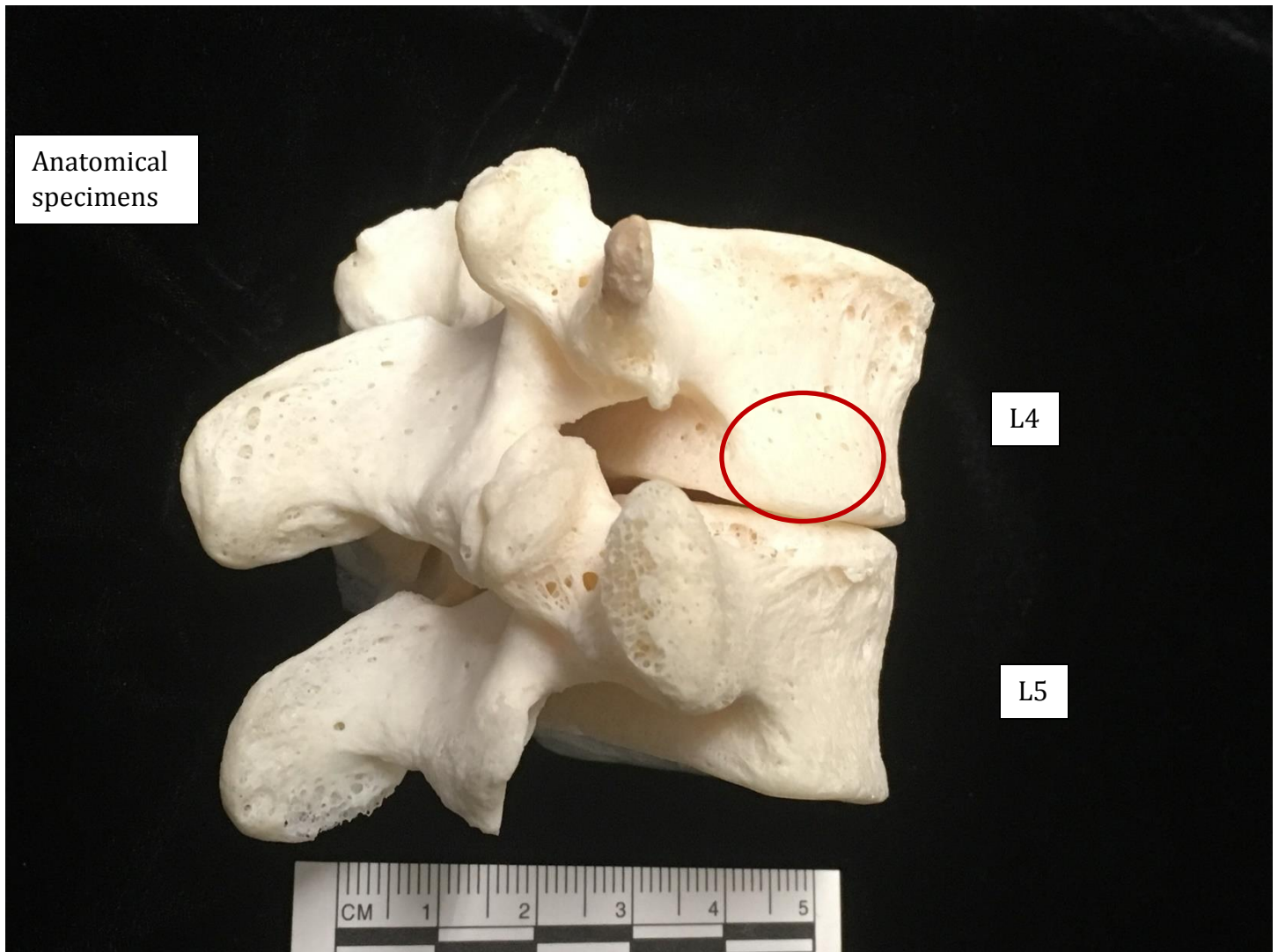
Fragment of lumbar vertebra #4 and complete lumbar vertebra #5, articulated. Posterior, angled to show part of right side. Note compression (creased area) of L4 body (arrow). Refer to Figure 26 for comparison with anatomical specimens exhibiting normal morphology. Discussion on page 8-9 of report.





**Figure 26.**

L4 and L5 anatomical specimens, articulated in same view as Figure 25 for comparison. Note lack of compression in same region as L4 fragment depicted in Figure 25.







**Figure 27.**

Lumbar vertebra #5. Superior surface, anterior to top image. Reactive and porous bone, entire surface, consistent with a traumatic or pathological condition. Discussion on page 8-9 of report.

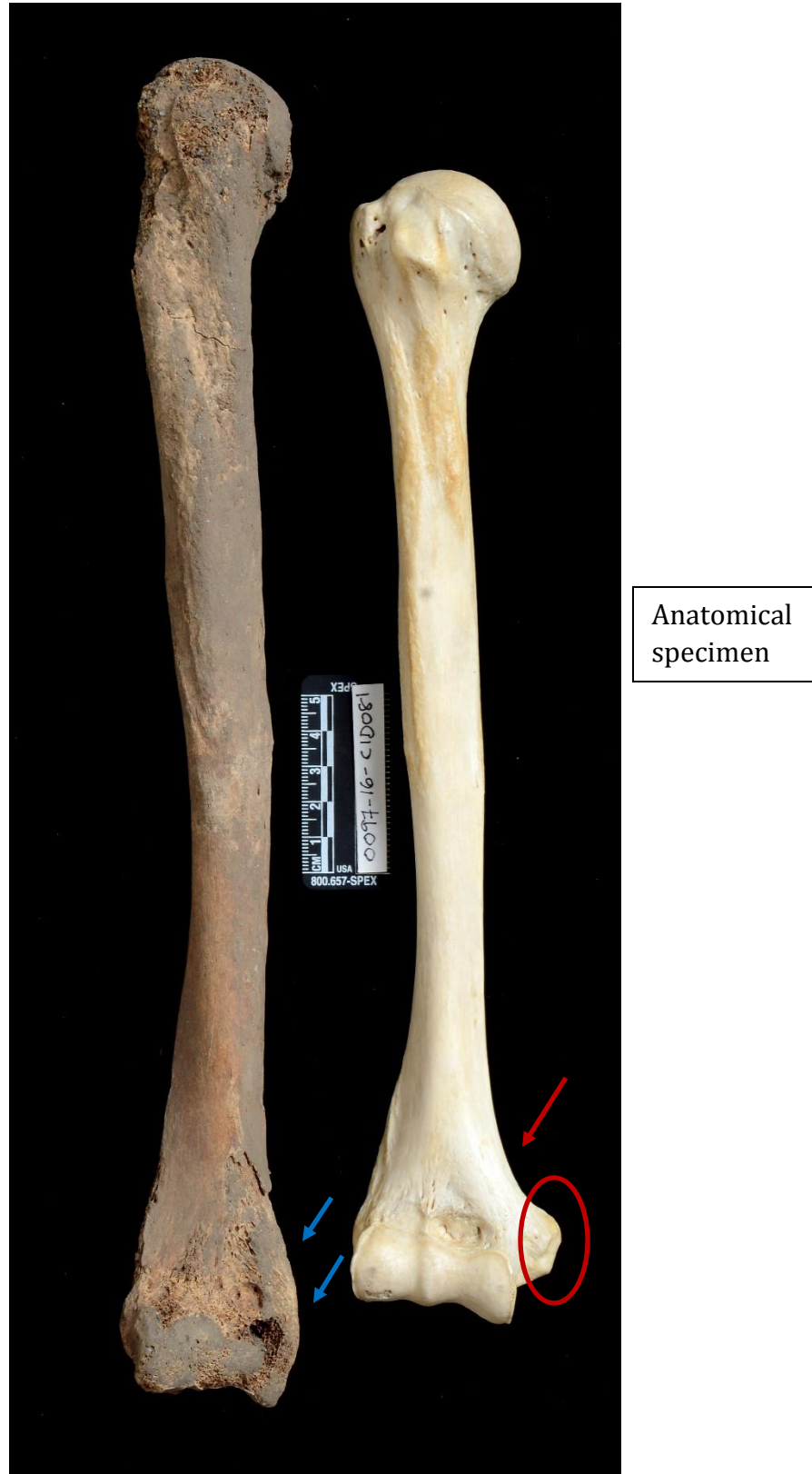






**Figure 28.**

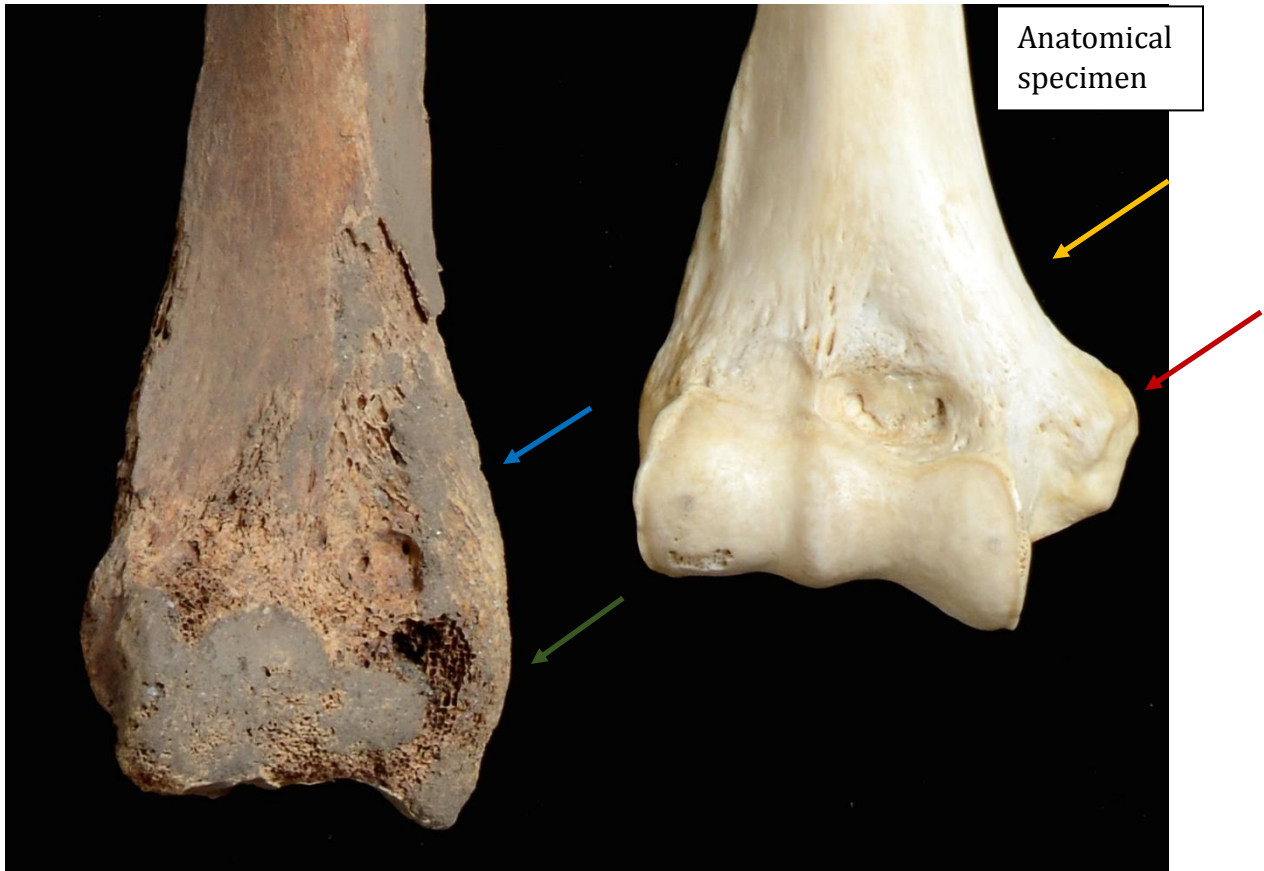
Right humerus, anterior. Bone on left side of image is the bone analyzed here. Right side of image depicts an anatomically normal right humerus. Note the medial epicondyle on the anatomical specimen (red circle) as well as how the medial side of the bone has a distinct angle which is absent in the analyzed specimen, despite some postmortem damage. See cropped close-up view, next figure.





**Figure 29.**

Cropped close up of Figure 28. Right humerus, anterior. Bone on the left side of image is the bone analyzed here. Right side of image depicts an anatomically normal right humerus. Note the medial epicondyle on the anatomical specimen (red arrow) as well as how the medial side of the bone has a distinct angle (yellow arrow) which is absent in the analyzed specimen (blue arrow) despite some postmortem damage. Green arrow depicts where medial epicondyle should be located. See Figure 28 for the scale. Discussion of the significance of this finding on page 9 of the report.





**Figure 30.**

Inferior side of right metatarsals 1-5. Medial to right side image. Note antemortem fracture by proximal articulation that extends at least through MT2-4 and caused medial angulation of proximal ends (see angled red lines). Fracture is most notable on MT2 given good preservation. Discussion on page 9 of the report.

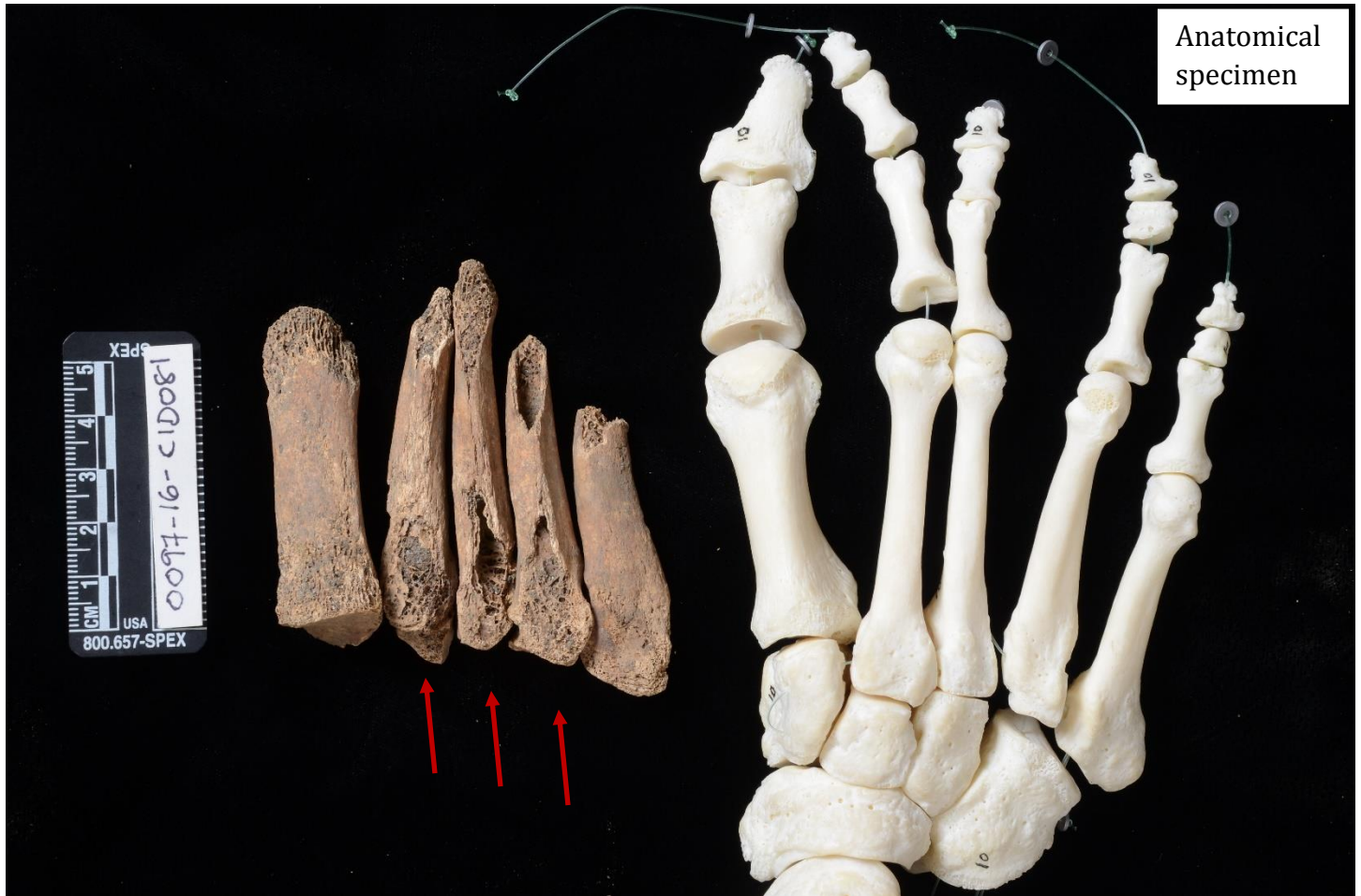





**Figure 31.**

Right metatarsals, superior; left side of image. Note postmortem damage (arrows) precluding assessment of whether the inferior fracture extended through to the superior side. Articulated anatomical specimen of root foot on right side of image for orientation. Discussion on page 9 of the report.

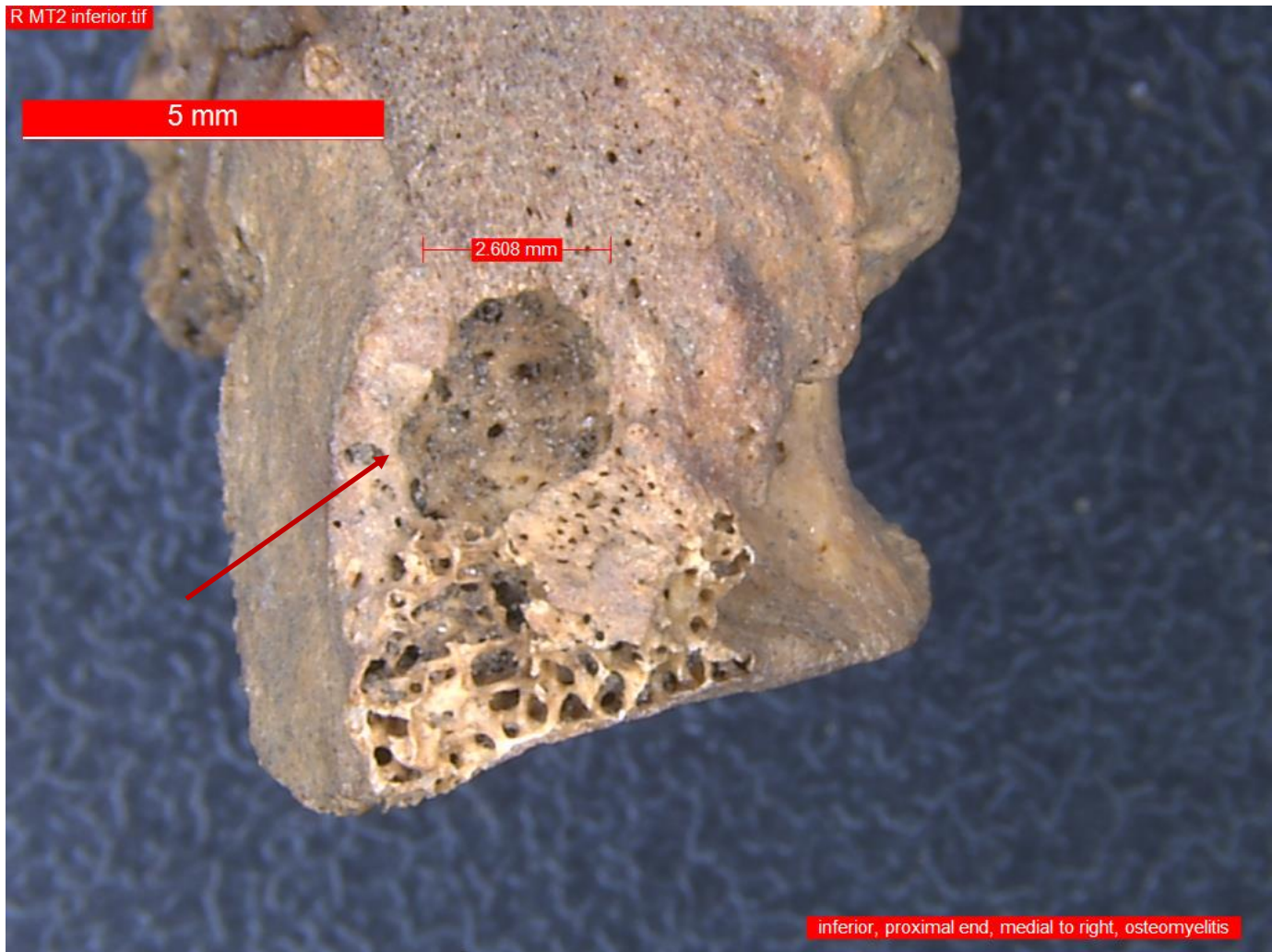






**Figure 32.**


Right 2<sup>nd</sup> metatarsal, proximal end, inferior side. Cloaca indicating osteomyelitis infection. Medial side to right of image. Discussion on page 9 of the report.





**Figure 33.**

Right 2<sup>nd</sup> metatarsal, proximal end, lateral side. Superior to left side image. Cloaca indicating osteomyelitis infection. Discussion on page 9 of the report.

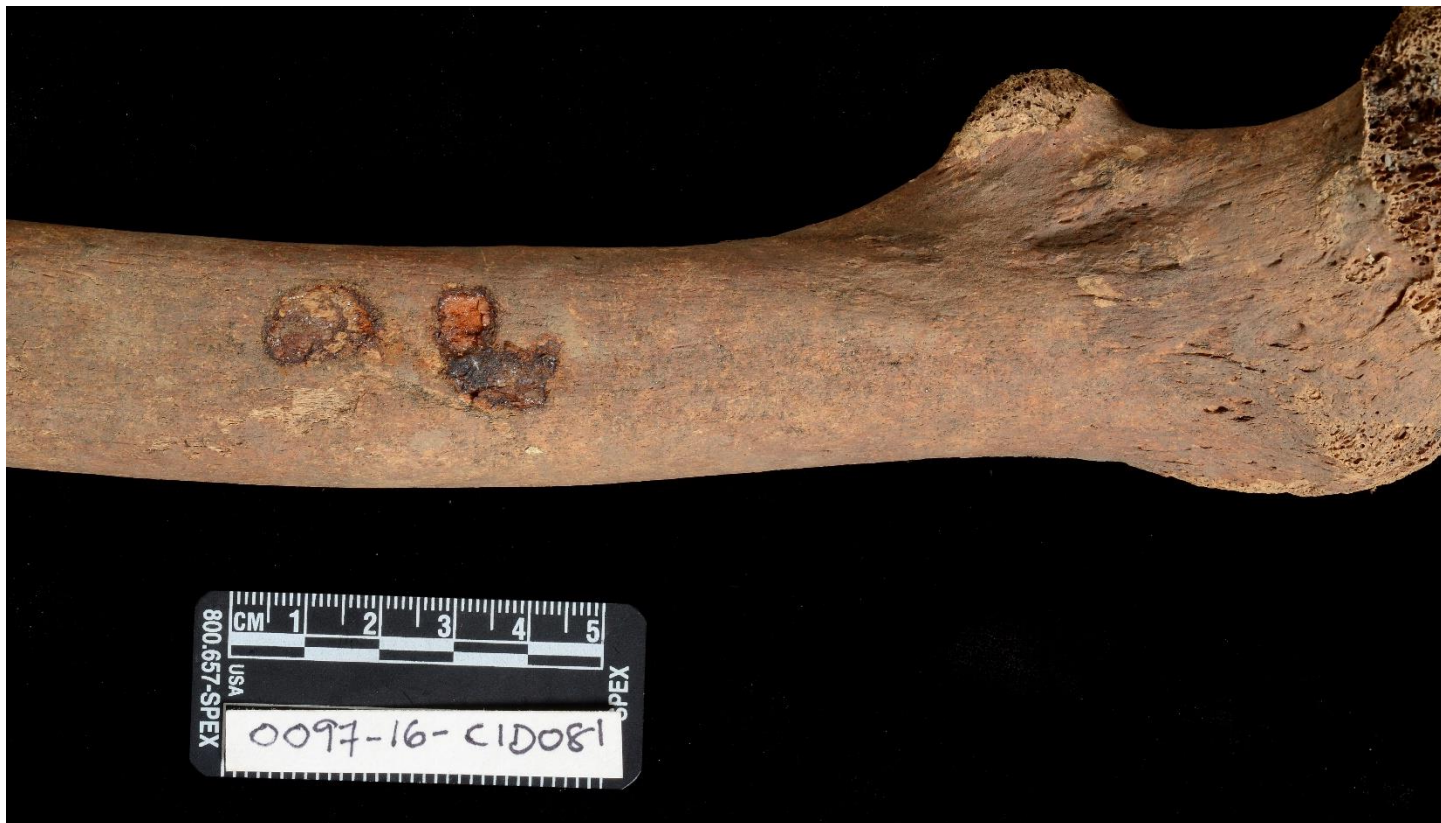





**Figure 34.**

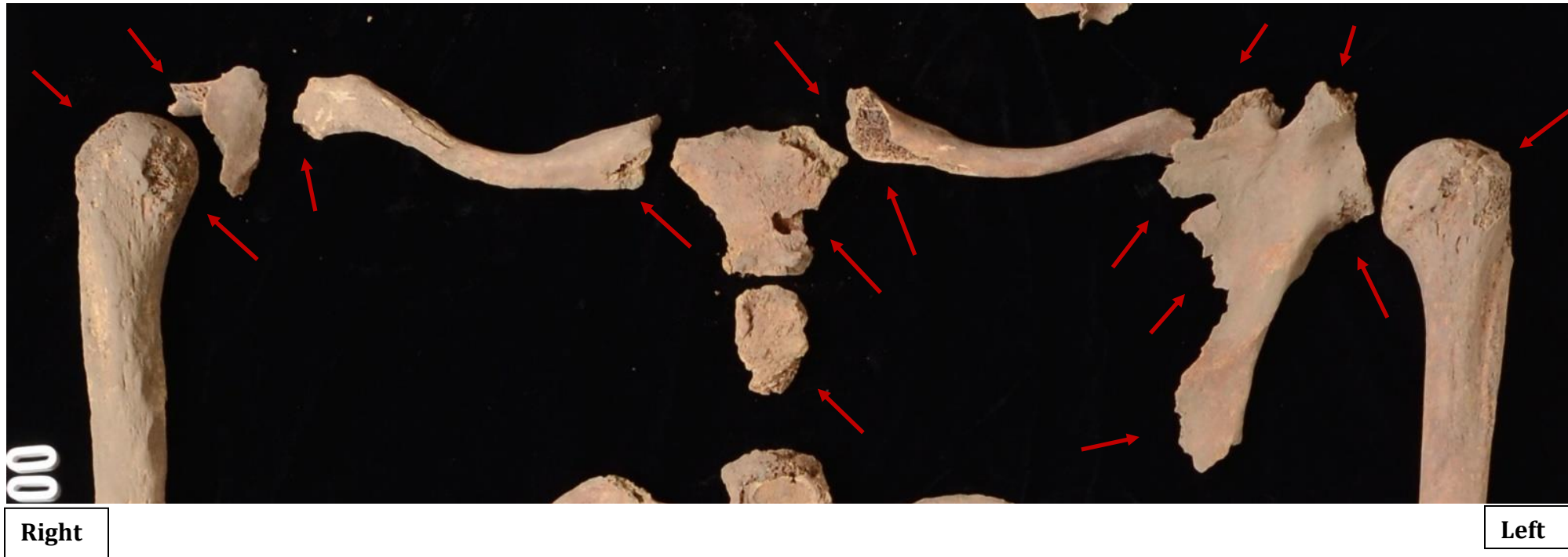
Areas of rust on left femur, anterior side. Proximal end to right side of image. Discussion on page 10 of the report.





**Figure 35.**

Close-up of right and left shoulders and breastbone, anatomical position. Anterior. Postmortem damage present (arrows), but no antemortem trauma. Postmortem damage typically results in sharp or jagged edges with discoloration of the broken ends, while antemortem trauma would have signs of healing. No healing is observed here. Note that only a small fragment of the right scapula is present, and the sternal body is only partially represented due to postmortem effects. (Cropped image of Figure 1, see that figure for the scale). Discussion on page 11 and 12 of the report.

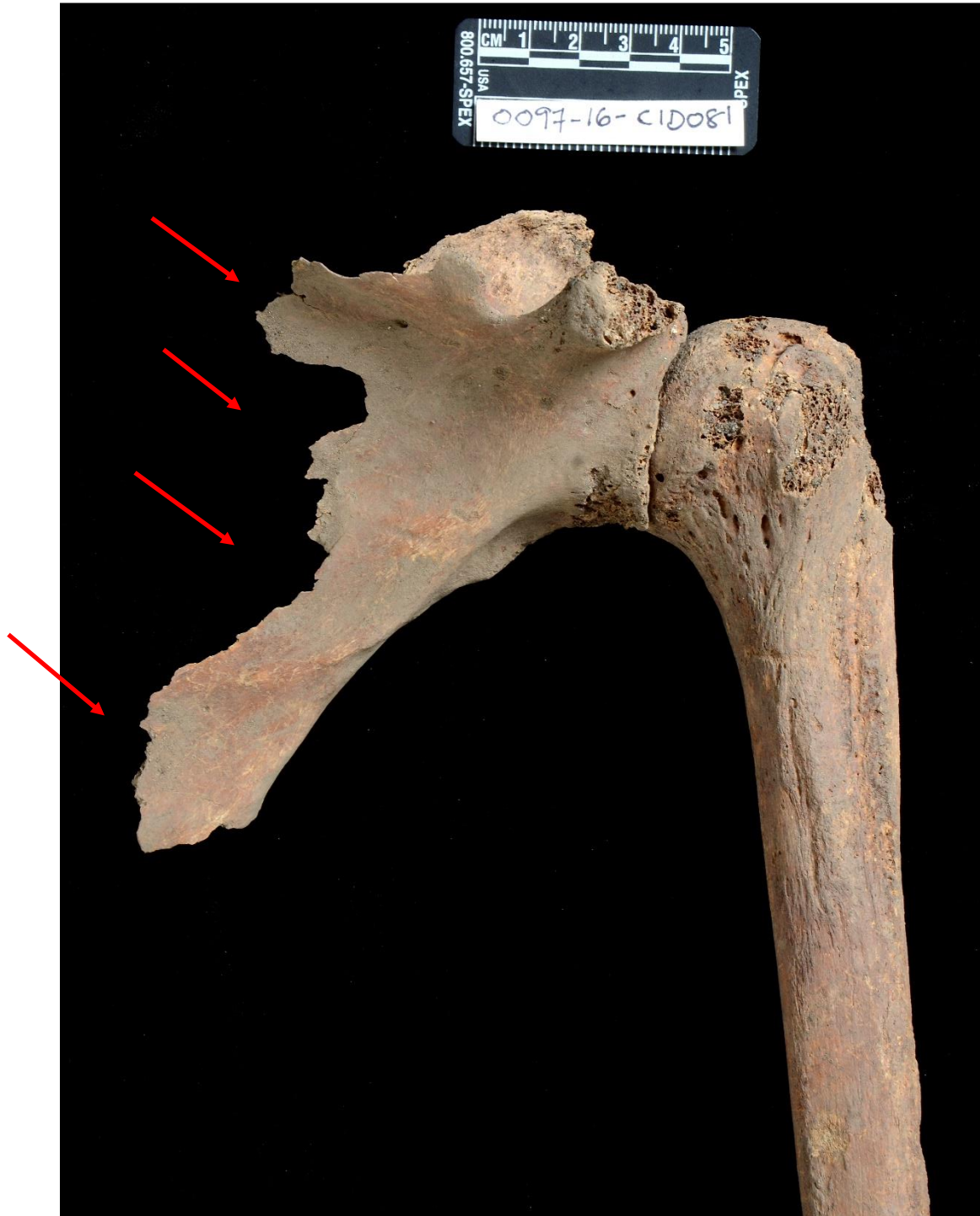





**Figure 36.**

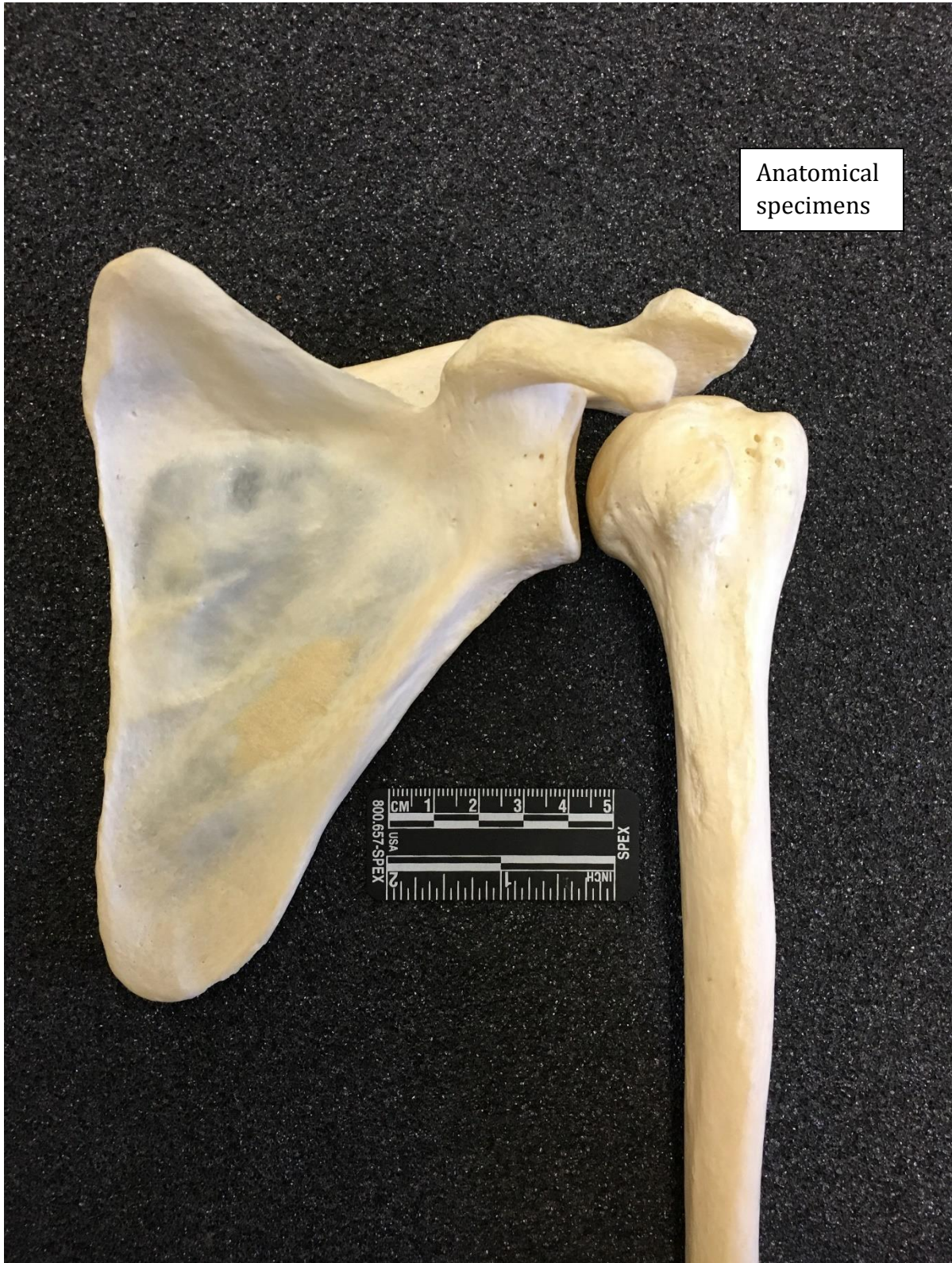Left humerus and scapula articulated, anterior side. No antemortem trauma, only postmortem damage. Note in particular the jagged edges of the scapular blade (red arrows). This postmortem damage is likely what the West Point surgeon mistook for antemortem shoulder trauma to the left shoulder. See Figure 37 for comparison with an undamaged and complete anatomical specimen. Discussion on pages 11 and 12 of the report.





**Figure 37.**

Anatomical specimen: left humerus and scapula articulated, anterior. Complete anatomical specimen for comparison with Figure 36. Note that the blade of the scapula is complete without jagged edges as in Figure 36.







**Figure 38.**

Right and left humeri, anterior. No antemortem trauma is present on the proximal articular ends (at the top of the image), only postmortem damage. The distal end fracture on the left humerus is postmortem.





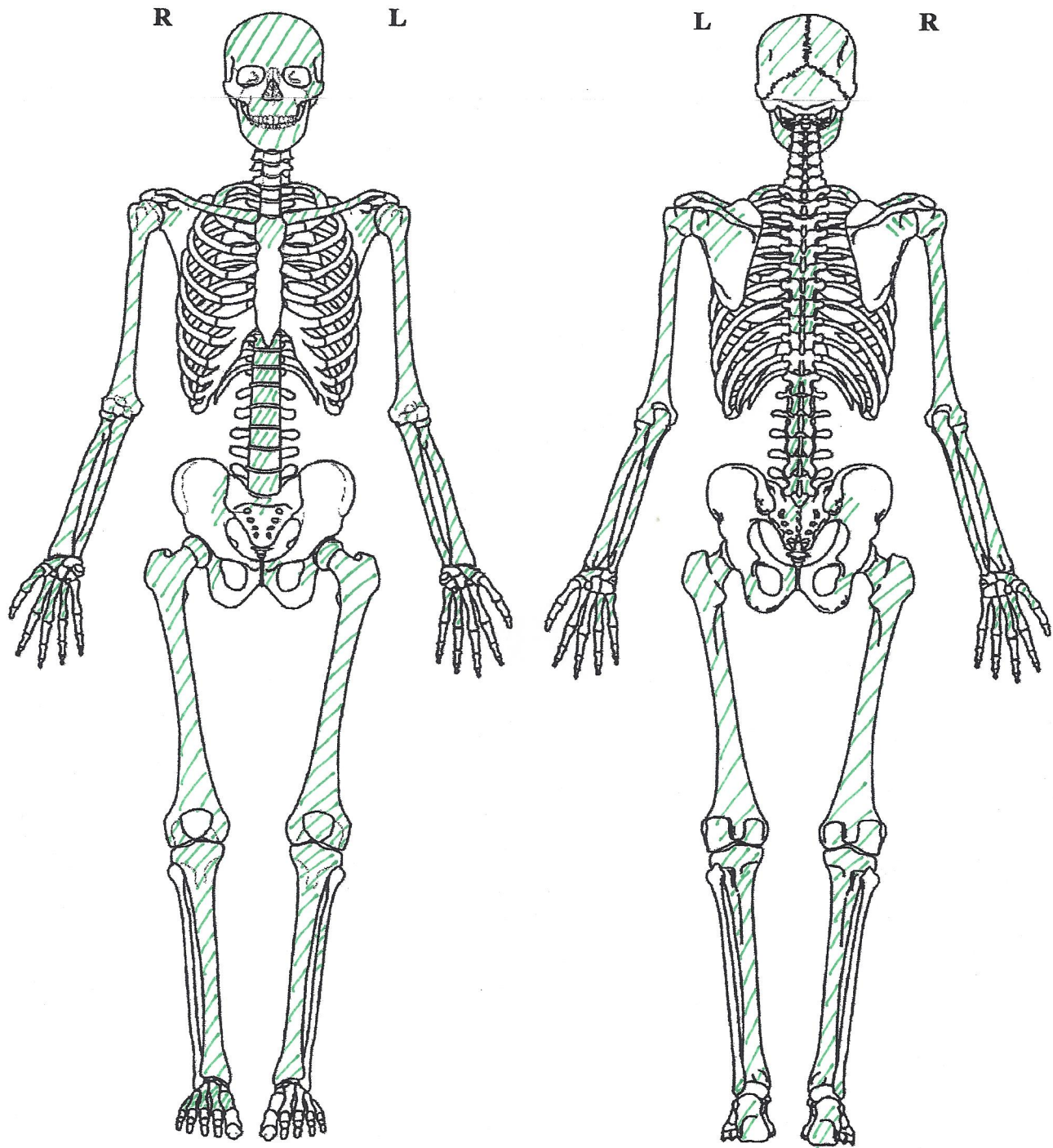
**Figure 39.**

Right and left humeri, posterior. No antemortem trauma is present on the proximal articular ends (at the top of the image), only postmortem damage (arrows). This postmortem damage is likely what the West Point surgeon mistook for antemortem shoulder trauma to the left shoulder. The fracture on the distal end of the left humerus is postmortem. Discussion on pages 11 and 12 of the report.









**KEY AND COMMENTS:**

Green slashed lines= element present  
No color= element not present or too fragmentary for inclusion  
Phalanges and ribs fragments not noted because not possible to discern which is which.  
Refer to Figures 1 and 2 in Appendix A.

Analyst Name E. DiGangi  
Date 12-23-16  
Duplicate for Report



**Figure B1.**


Cranial (left), vertebral (center), and rib (right) fragments.





**Figure B2.**

Undetermined fragments, including some pelvic fragments.







03-16  
 BUFA CASE # 0094-16-CID051

Dental Summary (Check all that apply):

- One or more teeth present
- Baby/Primary Teeth present
- Filling or Crown Present
- Removable Dentures
- Cemented Bridge
- Implants
- Braces
- Retainer
- Root Canal
- Upper Jaw Present
- Upper Jaw Had No Teeth During Life (Edentulous)
- Lower Jaw Present
- Lower Jaw Had No Teeth During Life (Edentulous)

Analyst Name: E. DiGangi Date 12.23.16  
 Duplicate for Report

	1	2	3	4	5	6	7	8	9	10	11	12	13	14	15	16	
Upper Right	A	A	A	O	O	O	A	P	P	P	O	A	O	A	A	O	Upper Left
Lower Right	O	A	A	A	O	O	O	O	P	P	O	A	O	A	A	O	Lower Left
	32	31	30	29	28	27	26	25	24	23	22	21	20	19	18	17	

- N = Natural tooth, no filling
- P = Postmortem Loss (open socket)
- B = Part of a Bridge
- A = Antemortem Loss (healed socket)
- C = Crown or Cap
- O = Other features (describe in comments)
- F = Filling, Inlay, Onlay, or Veneer
- I = Impacted
- R = Root Canal

**DENTAL COMMENTS:**

- 4I: Occlusal wear, Apical caries at CES distally, calculus
- 5: occlusal wear consistent with a pipe stem
- 6: occlusal wear consistent with a pipe stem
- 11: only part of root present, rest of tooth destroyed by caries Access chara present.
- 12: ATM loss but recent before death - not fully healed
- 13: occlusal wear
- 15: ATM loss but recent before death - not fully healed
- 16: occlusal wear, taken for DNA
- 33: covered in calculus
- 34: ATM loss but recent before death - not fully healed
- 38: occlusal wear consistent with a pipe stem, Calculus build up lingually
- 37: Same as 35 - has what could be a hypoplastic defect
- 36: occlusal wear
- 35: occlusal wear
- 34a: occlusal wear
- 30: Root present, rest of tooth lost to caries
- 17: occlusal wear and postmortem damage to crown





# APPENDIX V

## DNA Analysis



**Prepared by D. Andrew Merriwether, Ph.D. and Cassandra Koch, B.A.** from the Merriwether Ancient DNA and Forensic Laboratory at Binghamton University.

### **Background to the Methods Used in this Study:**

We received three elements (a tooth, a femur and a phalange) from my colleague at Binghamton University, Dr. Liz DiGangi. From these elements we were to extract DNA, verify its authenticity, and attempt to determine the sex of the individual. DNA extraction involved sterilizing the outside surfaces of the elements with bleach and ultraviolet light. This was to destroy or damage any contaminating DNAs on the outer surfaces due to prior handling. Interior portions of the elements were then drilled and the bone or tooth powder was collected. To separate the cells containing DNA from the bone or tooth matrix, we decalcified the bone and tooth powder with EDTA. We then freed the DNA from the proteins by using the enzyme "Proteinase K" to destroy the proteins. This breaks apart proteins but does not harm DNA. We then captured the DNA on a filter designed to bind DNA (but not protein). Proteins and other molecules pass through the filter while DNA stays bound to it until released. We then released the DNA into a sterile tube and it was then ready to copy. DNA is copied (amplified) by the polymerase chain reaction (PCR). This technique mimics the way our own cells copy their DNA before cells divide, but does it in repeated cycles, rather than just once, yielding billions of copies of the original molecules. Even though there is very little intact DNA left in ancient bone (DNA degrades very quickly after death), PCR often makes it possible to make enough copies of any surviving intact pieces for us to do genetic testing with the samples.

There are two major problems inherent in all ancient DNA research (including all forensic DNA work using samples from deceased individuals): 1) contamination from modern sources and 2) inhibition of PCR by acids in the soil or breakdown products of DNA or of the cells. To prevent contamination, we work in a custom-designed and -built ancient DNA and forensics lab. The lab has ultra-HEPA-filtered air (anything smaller than 0.2 microns is filtered out of the air). It has serial positive pressure air, so that the innermost rooms (where with drill the bones) have the highest pressure. This creates an environment where air is pushed out of the room when doors are open, preventing DNA from floating in from elsewhere in the building. We have UV lights over all surfaces and floor drains in the floor. The floor drains allow us to mop and wipe down the entire lab with 10-30% bleach (bleach destroys DNA). The UV light damages DNA, making it un-copy-able using PCR. We wear full-body covering lab gear, so that every inch of our bodies is covered, and we only work on the samples inside glove boxes. This is to separate us from the samples so that our DNA does not get into the extractions. We run negative controls with no DNA present to test for contamination. All reagents used in the ancient DNA lab are dedicated and only opened or made in that lab. aDNA and forensic reagents have never been in a modern DNA lab or exposed to modern DNA. Inhibition cannot be prevented, but it can sometimes be overcome with serial dilutions. If we can dilute the inhibitor enough, PCR can start working again. Sometimes it is not possible to dilute the inhibitor enough and still have any DNA left. Extracting a different element or using a different extraction technique may be necessary.

We attempted several different kinds of analyses of the extracted DNA. We sequenced the most variable part of human mitochondrial DNA (called the control region or hypervariable

region). Mitochondrial DNA (mtDNA) is strictly maternally inherited (you get all from your mom and none from your dad, only women can pass it on). MtDNA does not recombine, so it is transmitted intact from generation to generation. MtDNA's genome has been completely sequenced since 1981, so we can easily do PCR on any individuals. If this individual has any putative relatives, mtDNA is the best chance of matching the remains up to a family or individual. We know the mtDNA sequences of everyone who has ever worked in my lab, so we can tell if the sequence we find matches any of them (a possible sign of contamination).

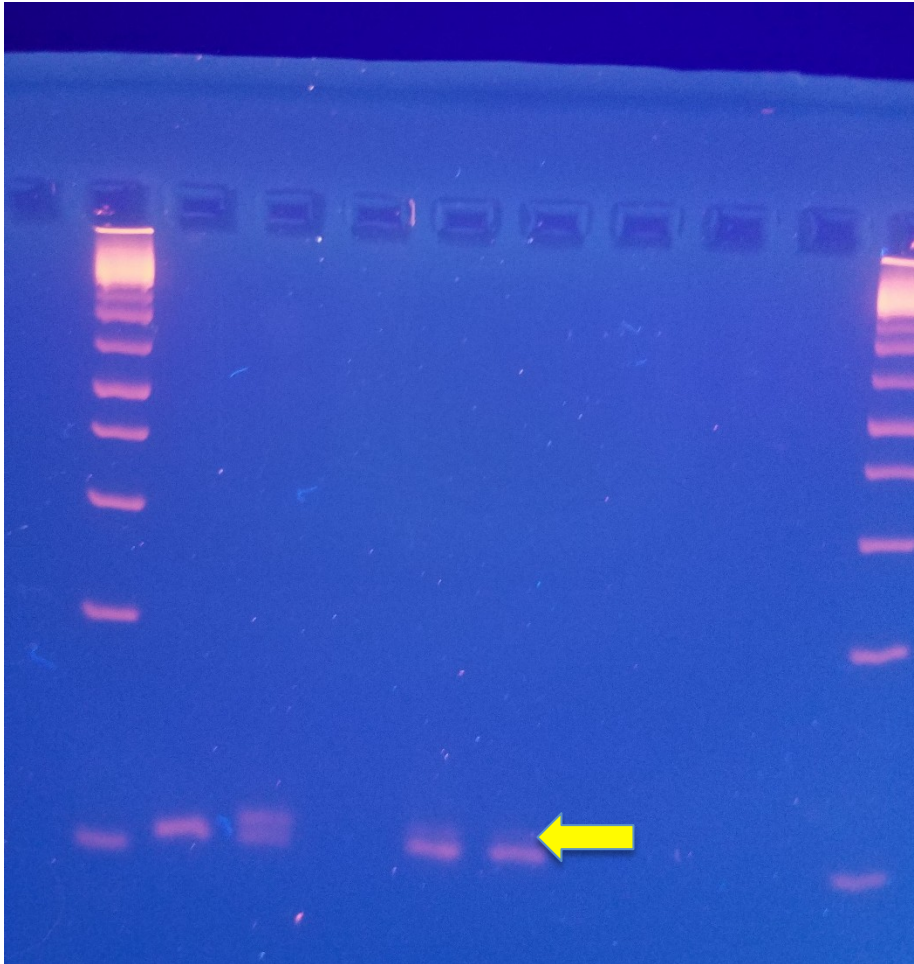
We also looked at markers on the sex chromosomes. Men have one X and one Y chromosome. Women have two Xs and no Y chromosomes. For the most part, genes are on the X or the Y but not both. The Amelogenin gene is on both and it does not recombine between the X and Y versions, so all women have one mutation, and all men a different mutation. Because of this, the Amelogenin gene is commonly used for sex identification of samples (the FBI, Scotland Yard, and Interpol all use it, as well as all state crime labs in the USA). The region we typed in this study is six base pairs shorter in women than in men, so if you amplify the DNA with PCR and electrophorese it though an agarose gel you can tell biological males from females by this gene. Agarose gels separate DNA by size. Small pieces move through it more quickly than larger pieces. DNA has a weak negative charge and if you put a current across the gel, the DNA gets pulled through it towards the positive electrode. Females will have one small band, males will have one small band (from the X chromosome) and one larger band (from the Y chromosome). If you see two bands, it is a male. One band indicates it is a female. To verify that this DNA came from the sample and not a modern contaminant, we tested our DNA extracts with markers called microsatellites (also called short-tandem-repeats or STRs). These are highly variable and it is highly unlikely they will match any two individuals at random. If these STRs matched anyone in the lab, we would suspect that we had contaminated them during the process. Contaminating DNAs are also in much better shape than ancient DNA (which has broken down into very small pieces), so if the ancient DNA works with larger markers that work on modern DNA, it may indicate contamination.

### **Results:**

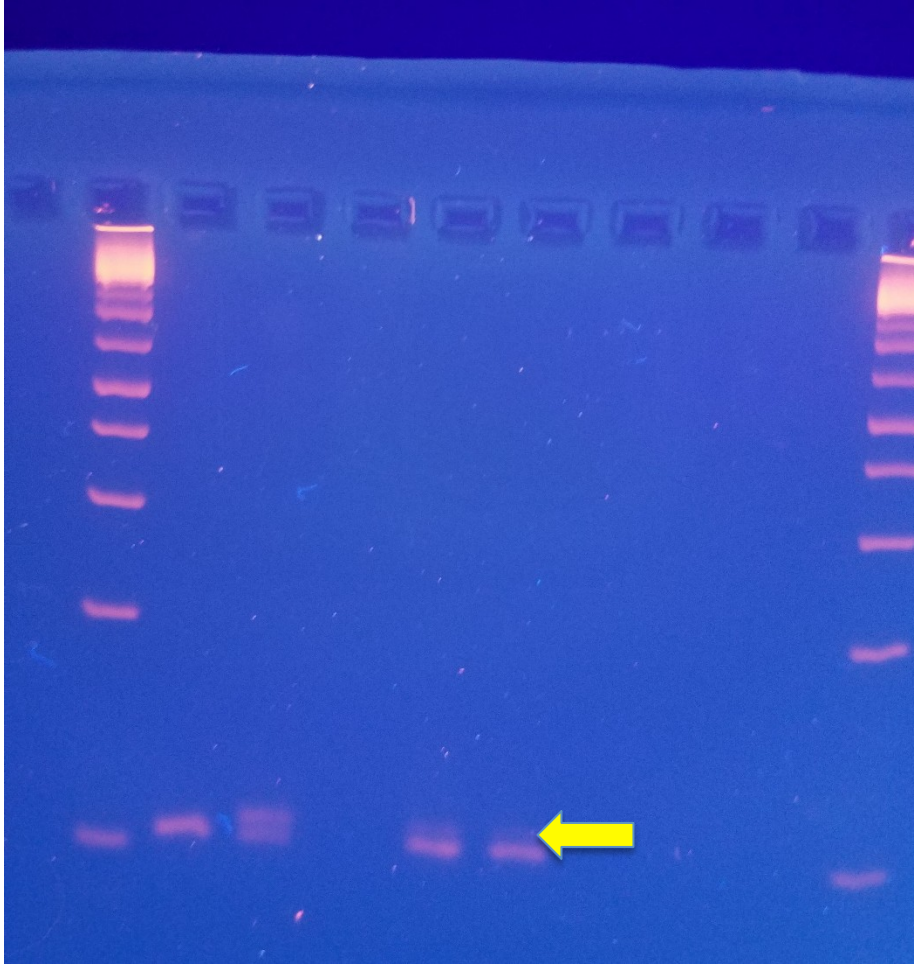
We conducted four separate extractions, all on different dates. One extraction was contaminated with modern DNA, likely from prior handling, and we discarded that extract. The other three came up clean, with all negative controls being negative and only one mtDNA sequence was found in each extract. We tried a number of different Y-chromosome STR primers that had been optimized for modern male DNA. None of them worked on the sample. We also tried one X-chromosome STR primer set and it also did not work on the sample. All worked for positive modern controls, indicating nuclear DNA preservation may be too poor for extensive genotyping.

We used amelogenin primers to try and detect a 6 bp deletion to determine sex. The Amelogenin gene is a gene involved in tooth development that is found on both the X and Y chromosomes in a region that does not recombine. Based on the gel results the sample looked to be male. The X-chromosome allele was supposed to be visible at 106 bp and the Y-chromosome allele was supposed to be at 112 bp. Therefore, males would have two bands and females would have one.

Two separate PCRs (both using PCR product as template) appear to have both bands present for the sample, indicating the presence of a Y-chromosome. The following two pictures are of the gels:



Lanes 1 and 10 are ladder. Lane 2 is a positive female control. Lane 3 is a positive male control. Lanes 4-7 are dilutions of the sample. Lanes 8 and 9 are negative PCR controls. The band for the X chromosome is clear in both dilutions of the sample (lanes 5 and 6) and there appears to be faint bands in both dilutions that show the Y-chromosome (yellow arrow points to the location).



Lane 1 and 8 are ladder. Lane 2 is a female positive control. Lanes 3, 5, and 7 are positive male controls. Lanes 4 and 6 are dilutions of the sample. There appears to be two bands in the lanes with the sample, but there was some streaking which made it difficult to tell for sure.

### Amelogenin Sequencing Summary:

The following are reference sequences for AMELY and AMELX:

Reference sequence: Homo sapiens amelogenin, Y-linked (AMELY), RefSeqGene on chromosome Y NCBI Reference Sequence: NG\_008011.1

CCCTGGGCTCTGTAAAGAATAGTG GGTGGATTCTTCATCCCAAATAAAGTG GTTTCT  
CAAG TGGTCCCAATTTTACAGTTCCTACCAT CAGCTTCCCAGTTTAAGCTCTGAT  
112 nucleotides

Reference sequence: Homo sapiens amelogenin, X-linked (AMELX), RefSeqGene on chromosome X NCBI Reference Sequence: NG\_012040.1

CCCTGGGCTCTGTAAAGAATAGTG TGTTGATTCTTTATCCCAGAT :GTTTCTCAAG  
TGGTCTGATTTTACAGTTCCTACCAC CAGCTTCCCAGTTTAAGCTCTGAT



106 nucleotides

Amel- A (Forward primer)

Shadrach-(reverse Primer)

The red areas indicate where the 6 bp deletion.

- Partial Amelogenin sequence from the sample:  
TGGTCCTGATTTTACAGTTCCTACCACCAGCTTCCCAGTTTAAGCTCTGAT  
This matches the last 51 bases of the AMELX reference sequence. The bp deletion is not included in the partial sequence.
- There are 3 SNPs in the partial sequence that differ between the AMELX and AMELY reference sequences. If there is an X and Y chromosome present we will see two peaks at each of the SNPs. Based on the electropherograms only one possible base (one peak) was present for the first two (highlighted as green and blue). For the last base (highlighted red) a C was called but there was also a T present. Based on these results it's not possible to tell if there is a Y as well as an X chromosome present in the sample.

o TGGTCCTGATTTTACAGTTCCTACCACAGCTTCCCAGTTTAAGCTCTGAT

Only T called

Only G called

C and T called, T smaller

### mtDNA Summary:

The following are sequences for the indicated region of the mitochondria:

- 16021-16094

CTGTTCTTTCATGGGGAAGCAGATTTGGGTACCACCCAAGTATTGACTCACCCATCA  
ACAACCGCT ATGTATTT

- 16106-16251

GCCAGCCACCATGAATATTGTACGGTACCATAAATACTTGACCACCTGTAGTACATA  
AAAACCCAATCCACATCAAAACCCCTCCCCATGCTTACAAGCAAGTACAGCAATC  
AACCTCAACTATCACAC ATCAACTGCAACTCC

- 16328-16429

CGTACATAGCACATTACAGTCAAATCCCCTCTCGTCCCCATGGATGACCCCCCTCAG  
ATAGGGGTC CCTTGACCACCATCCTCCGTGAAATCAATATCCCGC

There is a single polymorphism at 16,356 (C instead of T) compared to the Anderson Reference Sequence. Based on the mtDNA analysis, the possible haplogroups the sample could belong to are M (M6a1a), C (C1a), and N (N1a2). To further narrow down the haplogroup, more of the mtDNA will need to be sequenced.

### Conclusions:

The sample is from a male. We attempted multiple Y and X primer sets to prove it was not modern contaminant. None worked on the ancient samples and all worked on the modern positive controls. This indicates to me that this is ancient DNA, and from a male, and not likely

to be modern contamination. The small sections of mtDNA were not very specifically diagnostic for any geographic region. Haplogroups M (M6a1a), C (C1a), and N (N1a2) have a wide distribution in Europe and Asia (and are not seen in indigenous African populations).

## APPENDIX VI

### Qualifications of Investigators





**Joseph Balicki, RPA**

**Regional Director**

5250 Cherokee Avenue, Suite 300

Alexandria, VA 22312

P: 703.354.9737 | F: 703.642.1837

jbalicki@chg-inc.com

**Education**

M.A.	The Catholic University of America	Anthropology	1987
B.A.	The George Washington University	Anthropology	1981

**Professional Certification and Awards**

1999	Registered Professional Archaeologist (RPA)
2007	Ben Brenman Archaeology Award, Alexandria Archaeological Commission
2011	Chairman’s Award for Achievement in Historic Preservation, Advisory Council on Historic Preservation

**Experience Profile**

Joseph Balicki is a graduate of the George Washington University and holds a Master’s degree in anthropology from the Catholic University of America. Mr. Balicki responsible for office management, staff scheduling, staff mentoring, development of budgets, quality assurance and the procurement of new business. He manages and supervises cultural resources projects including Phase I identification, Phase II evaluation, and Phase III data recovery investigations under Sections 106 and 110, as well as local and state regulations. Additionally, his duties include developing scopes of work, research designs, and budgets; interfacing with clients and review agencies; directing research, field investigations, analysis, and report preparation; and monitoring schedules and budgets. Clients include the private sector, as well as local, state and federal agencies.

Mr. Balicki has over 36 years of experience, 26 at this firm, in North American archeology and has been involved in investigations of sites ranging from the Paleo-Indian through Historic periods. He has supervised or assisted various archeological survey and testing programs in Virginia, Maryland, Washington, D.C., Massachusetts, Pennsylvania, New Hampshire, Indiana, North Carolina, South Carolina, and Louisiana. Mr. Balicki is a nationally recognized expert on the Archeology of Civil War sites. He is proficient in conducting KOCO analysis, primary research, and metal detector surveys on Civil War archeological sites ranging from fortifications, earthworks, battlefields, winter quarters, cantonments and front-line temporary camps. Mr. Balicki is author or co-author of 132 cultural resources reports, 13 scholarly articles, and 32 papers presented at professional meetings. Mr. Balicki is an instructor for the RPA course Advanced Metal Detecting for the Archaeologist.

**Key Projects**

2011-16 **Statewide Cultural Resources Consulting Services.** Project Manager. Virginia Department of Transportation, Richmond, Virginia.

2011-2016 **Cultural Resources Services for the Army Corps of Engineers, St. Louis District, Missouri.** Project Manager/Principal Investigator. The Mandatory Center of Expertise for the Curation and Management of Archaeological Collections, St Louis District, The U.S. Army Corps of Engineers.

2011-2014 **Veterans Curation Project (VCP) Alexandria, Virginia Laboratory.** Project Manager. The Mandatory Center of Expertise for the Curation and Management of Archaeological Collections, St Louis District, The U.S. Army Corps of Engineers.

2013-2014 **Fort Ward Park and Museum Area Management Plan, City of Alexandria, Virginia.** Principal Investigator. Lardner/Klein Landscape Architects, P.C., Alexandria, Virginia and the City of Alexandria.

2013-2014 **Aldie, Middleburg, and Upperville Battlefield Preservation Plan American Battlefield Protection Program (Grant # ga-2255-12-013) Loudoun County, Virginia.** Principal Investigator. Mosby Heritage Area Association, Marshall, Virginia.

2011-2013 **Archeological Evaluation for the Proposed Chapel of the Ages at the Virginia Theological Seminary Alexandria, Virginia.** Project Manager/Principal Investigator. Advanced Project Management, Inc., Chantilly, Virginia and Virginia Theological Seminary, Alexandria, Virginia.

2011-2012 **Cultural Resource Investigations, Aquia Creek Battlefield. American Battlefield Protection Program, National Park Service (Grant # ga-2255-10-021) Stafford County, Virginia.** Project Manager/Principal Investigator. Stafford County Department of Economic Development, Stafford, Virginia.

2009-2011 **Cultural Resources Services (34 Cultural Resources projects) for the Eastern United States.** Project Manager/Principal Investigator. The Mandatory Center of Expertise for the Curation and Management of Archaeological Collections, St Louis District, The U.S. Army Corps of Engineers.

2001-2009 **Cultural Resources Investigations at Multiple Sites at Marine Corps Base, Quantico, Stafford and Prince William Counties, Virginia.** Project Manager/Principal Investigator. EDAW, Alexandria, Virginia.

### ***Selected Publications***

2014 The Fall 1863 Bivouac of the 14th Connecticut Infantry: Archeological Investigations of Troops on Active Campaign. In *From These Honored Dead: Historical Archaeology of the American Civil War*, Clarence Geier, Douglas Scott, and Larry Babits, editors. University Press of Florida, Gainesville, Florida.

2007 Landscape use During the Potomac River Blockade. In *Fields of Conflict*, Douglas Scott, Lawrence Babbitts, and Charles Haecker editors. Praeger Security International, Westport, Connecticut.



## W. Brett Arnold, RPA

### Project Archaeologist

5250 Cherokee Avenue, Suite 300

Alexandria, VA 22312

P: 703.399.4487 | F: 703.642.1837

wbarnold@chg-inc.com

### Education

M.S.	University of Wisconsin - Milwaukee	Anthropology	2014
B.A.	The College of Wooster	Archaeology	2011

### Professional Certification and Specialized Training

2014 Registered Professional Archaeologist (RPA)

### Experience Profile

W. Brett Arnold is a graduate of the College of Wooster and holds a Master's degree in anthropology from the University of Wisconsin – Milwaukee. Mr. Arnold's main skills include technical writing and editing, and he has worked on both archaeological and dendrochronological field reports. He spent two years managing and supervising projects for Anne Arundel County, Maryland's Lost Towns Project research consortium, and the preceding three working at various cultural resource management firms in Pennsylvania, Wisconsin, and Maryland. He has a broad range of field experience, including Phase I identification, Phase II evaluation, and Phase III data recovery at sites ranging from Archaic and Woodland resource procurement camps to eighteenth century plantations and nineteenth and twentieth century cemeteries. Additionally, Mr. Arnold has extensive experience in managing geospatial data through total station survey and GIS. He has directed 8 field projects, managed 5 historic research and public outreach projects, authored or coauthored 11 field reports, and given 5 paper presentations at professional conferences and symposia. Mr. Arnold has a total of 5 years experience in archaeology and cultural resource management and 2 years experience supervising archaeological field projects.

### Key Projects

2016 **Archaeological Survey for the Replacement of the Interstate 64 Bridges over Route 156, Henrico County, Virginia.** Project Archaeologist. Co-directed fieldwork and co-authored report. The Virginia Department of Transportation, Richmond District, Colonial Heights, Virginia.

2016 **Cultural Resources Survey for the Widening of U.S. Route 1 from Napper Road to Mt. Vernon Highway, Fairfax County, Virginia.** Project Archaeologist. Co-directed fieldwork. The Virginia Department of Transportation, NOVA District, Fairfax, Virginia.

2016 **Archaeological Survey for the Route 621 Ivy Creek Bridge Replacement Project, Bedford County, Virginia.** Project Archaeologist. Co-directed fieldwork and co-authored management summary. The Virginia Department of Transportation, Western Region, Salem, Virginia.

2016 **Metal Detection Survey for the Central Fauquier County Sports Complex, Fauquier County, Virginia.** Project Archaeologist. Conducted survey. Fauquier County Parks and Recreation, Warrenton, Virginia.



2016 **Phase IA Archaeological Survey for the DC United Soccer Stadium Project, Washington, D.C.** Project Archaeologist. Directed fieldwork and co-authored letter report. DC United, Washington, D.C.

2016 **Pedestrian Survey to Ground Truth Historic Map Resources at the James River and Presquile National Wildlife Refuges, Chesterfield and Prince Georges Counties, Virginia.** Project Archaeologist. Directed fieldwork and co-authored report. The U. S. Fish and Wildlife Service, Hadley Massachusetts.

2016 **Phase II Archaeological Evaluation of Sites 44FX1499 and 44FX1931, Fairfax County and Fort Belvoir, Virginia.** Project Archaeologist. Co-directed fieldwork. Angler Environmental, Richmond, Virginia.

2016 **Cultural Resources Survey for the Rolling Road (Route 638) Widening Project, Fairfax County, Virginia.** Project Archaeologist. Directed fieldwork and co-authored report. The Virginia Department of Transportation, NOVA District, Fairfax, Virginia.

2015 **Generals Highway (MD-178) Project.** Project Manager. Managed overall research program, directed fieldwork, and co-authored interim reports. Anne Arundel County, Annapolis, Maryland.

2015 **Field of Dreams Project.** Historic Research Consultant. Directed student research and design for exhibits and provided support for a Smithsonian traveling exhibit. Galesville Community Center, Galesville, Maryland.

2015 **Orruck Shore 2015 Phase I.** Project Manager. Directed Phase I fieldwork and coauthored report. Gibson Island Historical Society, Gibson Island, Maryland.

2014 **Romany Road Fall 2014 Project.** Project Manager. Supervised fieldwork and coauthored report. Gibson Island Historical Society, Gibson Island, Maryland.

2014 **Millersville Station Phase I.** Field Director. Directed fieldwork and coauthored report. Anne Arundel County, Annapolis, Maryland.

2013 **Milwaukee County Institutional Grounds Cemetery Phase III.** Mapping Technician. Ran total station for field survey and managed GIS data. Historic Resource Management Service, Milwaukee, Wisconsin.

### ***Selected Reports and Publications***

2016 "Where the Past Meets the Present with a Promise: Community Impact of History-Based Outreach in Galesville, Maryland." Paper presented at the 2016 Annual Meeting of the Society for Historical Archaeology, Washington, D.C.

2015 "Tracing the Generals Way: GIS Reconstruction of MD-178's Original Track." Paper presented at the 4<sup>th</sup> Biannual Mount Vernon GIS Symposium for Historic Resources, Mount Vernon, Virginia.

**Curriculum Vitae**  
**Elizabeth A. DiGangi, PhD, D-ABFA**

**Address**

Department of Anthropology  
4400 Vestal Parkway East  
Binghamton, NY 13902  
(607) 777-4339  
digangi@binghamton.edu

**Education**

- 2008            Ph.D., *University of Tennessee*, Biological Anthropology
- 2002            M.A., *State University of New York at Buffalo*, Biological Anthropology
- 1999            B.A., *State University of New York at Buffalo*, *magna cum laude*  
Joint major, Anthropology and History, *with highest distinction*

**Certification**

- 2015            Diplomate #103, *American Board of Forensic Anthropology*

**Research Interests**

Forensic anthropology, human rights, population-specific standards, age-at-death estimation, ancestry and social race, trauma analysis, bioarchaeology, paleopathology, prehistoric and historic health, stress, and well-being, Latin America, Caribbean, Europe, North America, North Africa

**Professional History**

- 2013-present    **Assistant Professor**, Department of Anthropology, *Binghamton University (State University of New York)*, Binghamton, New York.
- 2008-2012      **Forensic Advisor/Forensic Anthropologist**, *International Criminal Investigative Training Assistance Program (ICITAP)*-Colombia, Bogotá, Colombia.
- 2006-2007      **Tenure-track Instructor**, *Pellissippi State Technical Community College*, Knoxville, Tennessee.

**Consultancies**

- May 2016        **Forensic Anthropology Advisor**, *International Criminal Investigative Training Assistance Program (ICITAP)*-Mexico, Mexico City, Mexico.
- March 2016     **Forensic Anthropology Advisor**, *International Criminal Investigative Training Assistance Program (ICITAP)*-Algeria, Algiers, Algeria.

- Nov 2015 **Forensic Anthropology Advisor**, *International Criminal Investigative Training Assistance Program (ICITAP)*-Algeria, Algiers, Algeria.
- July 2015 **Technical Assessor**, *ANSI-ASQ National Accreditation Board*, Houston, Texas.
- May 2014 **Forensic Anthropology Advisor**, *International Criminal Investigative Training Assistance Program (ICITAP)*-Algeria, Algiers, Algeria.
- Dec 2013 **Forensic Anthropology Advisor**, *International Criminal Investigative Training Assistance Program (ICITAP)*-Algeria, Algiers, Algeria.
- Feb 2011 **Forensic Anthropology Advisor**, *International Criminal Investigative Training Assistance Program (ICITAP)*-Mexico, Mexico City, Mexico.

### **Continuing Education**

- 2016 Workshop: The AAFS Human Rights and Humanitarian Resource Center. American Academy of Forensic Sciences, Las Vegas, Nevada.
- 2015 Skeletal Trauma Analysis Course, Mercyhurst University, Erie, Pennsylvania.
- 2014 Skeletal Trauma Analysis Course, Mercyhurst University, Erie, Pennsylvania.
- 2012 Workshop: Preparation and Strategic Planning for Accreditation of Forensic Laboratories Based on the ISO/IEC 17025 International Standard. American Academy of Forensic Sciences, Atlanta, Georgia.
- 2011 Workshop: Fordisc. American Academy of Forensic Sciences, Chicago, Illinois.
- 2011 Workshop: Method Validation and Estimating the Uncertainty of Measurements in the Modern Forensic Laboratory for Compliance With ISO/IEC 17025:2005. American Academy of Forensic Sciences, Chicago, Illinois.
- 2010 Workshop: Taphonomy of Bone Destruction: Information Lost, Information Gained. American Academy of Forensic Sciences, Seattle, Washington.
- 2010 Workshop: The Forensic Investigation of Human Remains From Armed Conflicts and Catastrophes. American Academy of Forensic Sciences, Seattle, Washington.
- 2009 Workshop: Advances in Archaeological Approaches to Crime Scene Investigation. American Academy of Forensic Sciences, Denver, Colorado.
- 2005 Paleopathology Short Course. University of Bradford, Bradford, England, U.K.

### **Languages Spoken**

- English – native speaker  
Spanish – fluent in reading, writing, speaking

## **Fieldwork**

- 2012 Hualcayán (northern highlands), Peru. (4 weeks). Tomb excavation and remains curation. PI Rebecca E. Bria and Elizabeth Cruzado Caranza.
- 2011 Hualcayán (northern highlands), Peru. (1 week). Tomb excavation. PI Rebecca E. Bria and Elizabeth Cruzado Caranza.
- 2006 Brimstone Hill Fortress National Park, St. Kitts, West Indies. (7 weeks). British officers' quarters. PI Gerald F. Schroedl.
- 2005 Brimstone Hill Fortress National Park, St. Kitts, West Indies. (6 weeks). Enslaved Africans' quarters. PI Gerald F. Schroedl.
- 2004 Brimstone Hill Fortress National Park, St. Kitts, West Indies. (7 weeks). Enslaved Africans' quarters. PI Gerald F. Schroedl.

## **Museum and Osteological Collection Research**

- 2015 Saleux Early Medieval Skeletal Collection. Seigneurie de Poutrincourt, France. (Two weeks). Mandibular morphology and juvenile age-at-death.
- 2013 Saleux Early Medieval Skeletal Collection. Seigneurie de Poutrincourt, France. (Two weeks). Collection curation.
- 2012 Antioquia Modern Skeletal Reference Collection. National Criminalistics and Forensic Sciences School. Medellín, Colombia. (One week). Population-specific standards.
- 2011 Antioquia Modern Skeletal Reference Collection. National Criminalistics and Forensic Sciences School. Medellín, Colombia. (One week). Population-specific standards.
- 2011 Colombian Skeletal Collection. National Institute of Legal Medicine and Forensic Sciences, Bogotá, Colombia. (One week). Population-specific standards.
- 2007 William M. Bass Donated Skeletal Collection, University of Tennessee, Knoxville, TN. Test of first rib aging method.
- 2007 Prehistoric Chilean Skeletal Material, Archaeological Museum of La Serena, La Serena, Chile. (5 weeks). Application of the Western Hemisphere Health Index.
- 2006 Tennessee Valley Authority Collection, Frank H. McClung Museum, University of Tennessee, Knoxville, TN. Application of the Western Hemisphere Health Index.
- 2006 William M. Bass Donated Skeletal Collection, University of Tennessee, Knoxville, TN. Markers of parturition.
- 2006 Tennessee Valley Authority Collection, Frank H. McClung Museum, University of Tennessee, Knoxville, TN. Differential diagnosis of one individual's pathological conditions.

- 2005 William M. Bass Donated Skeletal Collection, University of Tennessee, Knoxville, TN. Orthopedic device identification.
- 2005 ICTY Biosamples from Kosovo, Department of Anthropology, University of Tennessee, Knoxville, TN. Age-at-death study from the first rib.
- 2005 Tennessee Valley Authority Collection, Frank H. McClung Museum, University of Tennessee, Knoxville, TN. Scurvy in prehistoric southeastern United States.
- 2005 Prehistoric Chilean Skeletal Material, Archaeological Museum of La Serena, La Serena, Chile. (One week). Application of the Western Hemisphere Health Index.
- 1999 Highland Park Skeletal Collection, Marion E. White Museum, University at Buffalo, Buffalo, New York. Maxillary sinusitis and dental disease.

**Teaching: *Binghamton University (State University of New York), Binghamton, New York***

- 2016 Anthropological Approaches to Human Rights (500 level)
- 2016 Introduction to Forensic Anthropology (300 level)
- 2015, 2017 Methods in Forensic Anthropology (500 level)
- 2015 (twice) Research Proposals in Skeletal Biology (500 level independent study)
- 2014 Human Rights and Policy (500 level independent study)
- 2014, 2015, 2017 Bones, Bugs, and Forensic Science (200 level)
- 2013, 2014, 2015 The Human Skeleton (300 level)
- 2013, 2014, 2015 Human Skeletal Biology (500 level)

**Teaching: *ICITAP-Algeria, Algiers, Algeria***

- 2015 Surface Scatter Recovery (continuing education)
- 2013 Forensic Archaeology Field Methods: Grave Excavation (continuing education)

**Teaching: *Columbia-Greene Community College, Hudson, New York***

- 2013 Introduction to Forensic Science (100 level)

**Teaching: *ICITAP-Colombia, Bogotá, Colombia***

- 2011 Advanced Workshop in Research Methods (continuing education)
- 2009 Research Methods for Forensic Anthropologists (continuing education)
- 2008-2011 (six times) Forensic Archaeological Field Methods (continuing education)
- 2010-2012 (four times) Advanced Forensic Archaeology (continuing education)
- 2008-2012 (six times) Bone Trauma Analysis (continuing education)
- 2010-2012 (five times) Osteology (continuing education)

**Teaching: *Pellissippi State Technical Community College, Knoxville, Tennessee***

- 2006, 2007 (twice per year) Prehistoric Archaeology (100 level)
- 2006, 2007 (twice per year) Introduction to Physical Anthropology (100 level)
- 2005, 2006, 2007 (twice per year) Intro to Cultural Anthropology - traditional, distance, online (100 level)

2005 Human Anatomy and Physiology I Laboratory (200 level)

**Teaching: *University of Tennessee, Knoxville, Tennessee***

2005, 2006 FBI Human Remains Recovery School (continuing education)  
2004, 2005 (twice per year) Human Origins Laboratory (100 level)  
2003 Human Anatomy Laboratory (200 level)

**Teaching: *State University of New York at Buffalo, Buffalo, New York***

1999, 2000, 2001, 2002 Primate Dissections (300 level)

**Forensic Anthropology/Bioarchaeology Casework and Technical Reports**

Dec 2016 Forensic Anthropology Case Report, Analysis of one human skeleton, submitted to Commonwealth Heritage Group, Alexandria, VA

Aug 2016 Forensic Anthropology Case Report, Analysis of one human skeleton, submitted to Onondaga County Medical Examiner's Office, Syracuse, NY

Feb 2016 Forensic Anthropology Case Report, Analysis of one human skeleton, submitted to Richard Giardino, Fulton County Sheriff, Fulton County, NY

Oct 2015 Forensic Anthropology Case Report, Analysis of one human skeleton, submitted to Kelly Storrs, Broome County Coroner, & Dr. James Terzian, Forensic Pathologist, Lourdes Hospital, Binghamton, NY

April 2015 Forensic Anthropology Case Report, Analysis of one human skull and femur, submitted to Dr. Blanche Borzell, Schuyler County Coroner, NY

April 2015 Forensic Anthropology Case Report, Analysis of one human skeleton, submitted to Tom Carman, Bradford County, PA County Coroner & Dr. James Terzian, Forensic Pathologist, Lourdes Hospital, Binghamton, NY

May 2014 Forensic Anthropology Case Report, Analysis of one human skeleton, Submitted to Dr. James Terzian, Forensic Pathologist, Lourdes Hospital, Binghamton, NY

March 2014 Forensic Anthropology Case Report, Analysis of one human skeleton, Submitted to Tom Carman, Bradford County, PA County Coroner

Nov 2013 Forensic Anthropology Case Report, Analysis of one human skeleton, Submitted to Dr. Howard Silcoff, Tompkins County, New York Medical Examiner

Oct 2013 Historic Archaeology Report, Analysis of three human skeletons, submitted to Dr. Nina Versaggi, Director of Public Archaeology Facility, Binghamton University

Nov 2012 Forensic Anthropology Case Reports, Analysis of three human skeletons, submitted to Chief Medical Examiner, Detroit, Michigan

- June 2007 *Human Skeletal Remains from Excavations at Brimstone Hill Fortress National Park, St. Kitts, West Indies, 2006*. Submitted to the Brimstone Hill Fortress National Park Society, St. Kitts, West Indies. Brimstone Hill Archaeological Report No. 30.
- June 2006 *Human Skeletal Remains from Brimstone Hill Fortress National Park, St. Kitts, West Indies, 2005*. Submitted to the Brimstone Hill Fortress National Park Society, St. Kitts, West Indies. Brimstone Hill Archaeological Project Report No. 27.
- June 2005 *Human Skeletal Remains from Excavations at Brimstone Hill Fortress National Park, St. Kitts, West Indies, July – August 2004*. Submitted to the Brimstone Hill Fortress National Park Society, St. Kitts, West Indies. Brimstone Hill Archaeological Project Report No. 25.

### **Invited Lectures**

- Mar 2016 *From the Fiscalia to the Gendarmerie: Capacity Building of Forensic Scientists in Colombia and Algeria*. Forensic Anthropology Society Conference, Texas State University, San Marcos, Texas.
- Oct 2015 *What's The Biological Profile Good for Anyway? Applications of Forensic Anthropology – Human Rights and Mass Disasters*. Department of Anthropology, University at Buffalo, Buffalo, New York.
- Sept 2015 *Jane, John, Fido, or Bambi? Differentiating Human from Non-Human Skeletal Remains*. New York State Association of County Coroners and Medical Examiners Fall 2015 Educational Conference, Rochester, New York.
- Jan 2015 *Lo que pasa es que: The Practice of Forensic Anthropology in Colombia*. Department of Anthropology, University at Buffalo, Buffalo, New York.
- Nov 2014 Public Talk: *Lo que pasa es que: The Practice of Forensic Anthropology in Colombia* Graduate Student Workshop: *An Example of Approaching Best Practices in Forensic Anthropology: Dealing with Bias*. Chico Forensic Conference, California State University Chico, California.
- March 2014 *Forensic Taphonomy: Animal Effects*. New York State Association of County Coroners and Medical Examiners Spring 2014 Educational Conference, Syracuse, New York.
- Feb 2013 *Lo que pasa es que: The Practice of Forensic Anthropology in Colombia*. Department of Anatomy and Neurobiology Forensic Anthropology Program, Boston University School of Medicine, Boston, Massachusetts.
- Nov 2012 *Lo que pasa es que: The Practice of Forensic Anthropology in Colombia*. Department of Behavioral Sciences, University of Michigan-Dearborn, Dearborn, Michigan.
- Oct 2012 *Desarrollando la Ciencia de la Antropología Forense en Colombia: Retos, Metas, y Oportunidades* (Developing the Science of Forensic Anthropology in Colombia: Challenges, Goals, and Opportunities). XV Simposio Internacional de Criminalística e Investigación Criminal (XV International Criminalistics and Criminal Investigation

Symposium) Sponsored by the National Police of Colombia, School of Criminal Investigation, Bogotá, Colombia.

Oct 2011 Invited panel member, *Investigation of Narco-Terrorism Related Murders and Clandestine Burials in Colombia*. The International Association of Chiefs of Police Annual Meeting, Chicago, Illinois.

### **Invited Lectures: On Campus**

April 2015 *Forensic anthropology in Colombia*. Global Medical Brigades Club. Binghamton University, Binghamton, New York.

Oct 2014 *Bones and Ballistics: Myth vs. Reality*. Mountainview College Residence Life Event Binghamton University, Binghamton, New York.

May 2014 *Structural Violence in Colombia: Relationship Between Health Care Access and Disease Manifestation*. Universities Allied for Essential Medicines, Binghamton University Chapter Global Health Conference, Binghamton, New York.

### **Presentations and Published Abstracts: Platform**

**DiGangi, EA**. October 2014. *Osteobiography of a Mummy Recovered from a Chullpa Machay Tomb from the Site of Hualcayán, Callejon de Huaylas Valley, in Peru's Northern Highlands*. Bioarchaeologists' Northeast Regional Dialogue. Ithaca, New York.

JD Bethard and **EA DiGangi**. 2013. *The Problem of Estimating Sex from the Skull: A Comparison of Methods Applied to a Modern Colombian Sample*. American Academy of Forensic Sciences Annual Meeting, Washington, D.C. Proceedings of the American Academy of Forensic Sciences 19: 440-441.

**EA DiGangi**, MD Morcillo, JH Vivas. 2012. *Advances in Victim Identification in Colombia*. American Academy of Forensic Sciences Annual Meeting, Atlanta, GA. Proceedings of the American Academy of Forensic Sciences 18: 391.

AH McKeown and **EA DiGangi**. April 2011. *If the Rum Don't Kill Me, I'll Live Until I Die: A Bioarchaeological Study of British Soldiers from St. Kitts, West Indies*. Society of American Archaeology Annual Meeting, Sacramento, California. Abstracts of the SAA 76th Annual Meeting pg. 214.

C Sanabria and **EA DiGangi**. 2011. *Development of the Colombian Skeletal Collection*. American Academy of Forensic Sciences Annual Meeting, Chicago, IL. Proceedings of the American Academy of Forensic Sciences 17: 338-339.

**EA DiGangi**. Oct 2010. *Entrenamiento de Antropología Forense en Colombia*. (Forensic Anthropology Training in Colombia). Latin American Association of Forensic Anthropology (ALAF) Annual Meeting, Manizales, Colombia.

IY Campos and **EA DiGangi**. 2010. *Forensic Anthropology in Colombia: Working Amidst Armed Conflict*. American Academy of Forensic Sciences Annual Meeting, Seattle,



Washington. Proceedings of the American Academy of Forensic Sciences 16: 409-410.

**EA DiGangi**, JD Bethard, EH Kimmerle, and LW Konigsberg. 2006. *A New Method for Estimating Age-at-Death From the First Rib*. American Academy of Forensic Sciences Meeting, Seattle, WA. Proceedings of the American Academy of Forensic Sciences 12: 283-284.

**EA DiGangi** and AH McKeown. 2005. *Human Skeletal Remains from Brimstone Hill Fortress National Park, St. Kitts, West Indies*. Society of Post-Medieval Archaeology Conference. Nevis, West Indies.

### **Presentations and Published Abstracts: Poster**

EE Hammerl, MK Moore, **EA DiGangi**, and HM Justus. April 2017. *A test of the mastication hypothesis on mandibular morphology using medieval and modern non-adult individuals*. American Association of Physical Anthropologists Annual Meeting, New Orleans, Louisiana.

A Lahouel, MY Guellati, H Grait, M Toumi, A Boudaba, B Djedouani, A Atrouz, A Djebbouri, M Benalia, A Mezhoudi, R Boussahla, A Slimani, JD Bethard, and **EA DiGangi**. February 2017. *Subaerial Bone Weathering in North Africa: An Experimental Study in Algiers, Algeria*. American Academy of Forensic Sciences Annual Meeting, New Orleans, Louisiana.

**EA DiGangi**. April 2016. *Forensic Anthropology Is Anthropology: How Participant Observation, Cultural Relativism, and Interviews Inform International Casework*. American Association of Physical Anthropologists Annual Meeting, Atlanta, Georgia. American Journal of Physical Anthropology 159(S62): 131.

JD Bethard, **EA DiGangi**, and LP Sullivan. March 2015. *Distinguishing Impairment from Disability in the Bioarchaeological Record: An Example from DeArmond Mound (40RE12) in East Tennessee*. American Association of Physical Anthropologists Annual Meeting, St. Louis, Missouri. American Journal of Physical Anthropology 156(S60): 85.

**EA DiGangi**. 2013. *Training and Empowerment in Forensic Anthropology on an International Level: How the Life's Work of Dr. Karen Ramey Burns Has Inspired Training in Colombia*. American Association of Physical Anthropologists Annual Meeting, Knoxville, Tennessee. American Journal of Physical Anthropology 150(S56): 113.

**EA DiGangi**. 2014. *Carnivore Modification or Pathology? Differential Diagnosis of Defects to Human Bone from a Chullpa Machay Tomb, Hualcayán, Callejon de Huaylas Valley, Peru's Northern Highlands*. Paleopathology Association Annual Meeting, Calgary, British Columbia.

**EA DiGangi**. 2010. *The Use of Strontium Isotopes to Examine Residential Mobility in the Semi-arid North of Chile: a Preliminary Study*. American Association of Physical Anthropologists Annual Meeting, Albuquerque, New Mexico. American Journal of Physical Anthropology 141(S50): 95.

**EA DiGangi**. 2008. *Prehistoric Health in Tennessee During Subsistence Transition Using the Western Hemisphere Health Index*. American Association of Physical Anthropologists Annual Meeting, Columbus, Ohio. American Journal of Physical Anthropology 135(S46): 90.

DL Hutchinson, **EA DiGangi**, MO Smith, and TK Betsinger. 2008. *Dental Defects in the Deciduous Dentition of Two Late Mississippian Period Subadults with Arguable Treponemal Disease: Cases of Possible Congenital Transmission*. American Association of Physical Anthropologists Annual Meeting, Columbus, Ohio. American Journal of Physical Anthropology 135(S46): 122.

**EA DiGangi** and JD Bethard. 2008. *A Test of An Age-at-Death Method Using the First Rib*. American Academy of Forensic Sciences Annual Meeting, Washington, D.C. Proceedings of the American Academy of Forensic Sciences 14: 351.

**EA DiGangi** and JD Bethard. 2007. *Differential Diagnosis of Cartilaginous Dysplasia and Probable Osgood-Schlatter's Disease in a Mississippian Individual from East Tennessee*. Paleopathology Association Annual Meeting, Philadelphia, Pennsylvania.

**EA DiGangi** and JD Bethard. 2007. *Skeletal Markers of Parturition II: Reanalysis of a Modern American Sample*. American Academy of Forensic Sciences Annual Meeting, San Antonio, TX. Proceedings of the American Academy of Forensic Sciences 13: 339.

**EA DiGangi**. 2006. *Scurvy in Tennessee: Juveniles from Archaeological Sites in the Southeastern United States with Evidence of Vitamin C Deficiency*. Paleopathology Association Annual Meeting, Anchorage, Alaska.

RJ Wilson, JD Bethard, and **EA DiGangi**. 2006. *Orthopedic Devices and the William M. Bass Collection: Implications for Forensic Anthropological Identification*. American Academy of Forensic Sciences Meeting, Seattle, Washington. Proceedings of the American Academy of Forensic Sciences 12: 289-290.

**EA DiGangi** and RL Jantz. 2004. *Dermatoglyphic Ridge Counts Compared To Short Tandem Repeats As Measures of Population Distance*. American Association of Physical Anthropologists Annual Meeting, Tampa, Florida. American Journal of Physical Anthropology 123(S38): 87-88.

**EA DiGangi**. 2001. *Maxillary Sinusitis As Related to Dental Infection*. American Association of Physical Anthropologists Annual Meeting, Kansas City, Missouri. American Journal of Physical Anthropology 114(S32): 59.

### **Grants, Awards, and Fellowships**

- |      |  |
|------|--|
| 2016 | National Institute of Justice Research and Development in Forensic Science for Criminal Justice Purposes Grant: <i>Development of a Skeletal Gunshot Atlas from Cranial Bone</i> (\$316,000). 2016-DN-BX-0155. |
| 2015 | Applied for Wenner-Gren Post-PhD Research Grant: <i>Assessing Biological Stress in Migrants and Non-migrants in Bogotá, Colombia: 1870-1970</i> (\$19,930, not funded.)  |
| 2007 | Grant Recipient, W.K. McClure Fund, University of Tennessee (\$3000)   |
| 2007 | William S. Pollitzer Award for essay, <i>Teaching of Human Evolution</i> (\$500)   |

- 2005 Grant Recipient, W.K. McClure Fund, University of Tennessee (\$3000)
- 2004 Tennessee Valley Authority Graduate Scholar in Archaeology Award (\$10,000)
- 2004 American Dermatoglyphics Association Student Prize for Poster Presentation, *Dermatoglyphic Ridge Counts Compared To Short Tandem Repeats As Measures of Population Distance* (\$200)
- 1999-2002 Arthur Schomburg Graduate Fellow, University at Buffalo (\$30,000)
- 1995-1999 Howard Hughes Undergraduate Fellow, University at Buffalo (\$5400)

**Peer Reviewer, Grants**

*National Science Foundation*

**Peer Reviewer, Journals and Book Publishers**

*International Journal of Osteoarchaeology*

*Homo*

*Elsevier – Academic Press*

**Program Review**

Boston University School of Medicine, Forensic Anthropology Masters Program, Dec 2015

**Professional Societies**

Lifetime Member, American Association of Physical Anthropologists

Fellow, American Academy of Forensic Sciences

Member, Paleopathology Association

Member, American Association for the Advancement of Science

Associate Member, New York State Association of County Coroners and Medical Examiners

**Professional Appointments**

Consultant, Human Identification Center, Medellín, Colombia

Adjunct Investigator, *Museo Arqueológico de La Serena*, La Serena, Chile

Secretary, *American Dermatoglyphics Association*, 2007-2010

**Department of Anthropology and University Service**

2016: Search committee member, Andean archaeology hire, Anthropology Department

Summer 2016: Member, creation of HARP common book class committee

2015-2016: Organizer of Anthropology Department's Speaker Series with support from the Harpur College Dean's Office. Theme: *Anthropology and Climate Change*. Three speakers.

2014-2015: Organizer of Anthropology Department's Speaker Series with support from the Harpur College Dean's Office. Theme: *Human Rights: Applied Approaches*. Six speakers.

2014-present: Member of Committee for Committees

2014: ad hoc Member of Calendar Committee

2015-2016: Anthropology Department representative for Human Rights TAE hire

**Public Service**

- Feb 2017 (upcoming) Expert witness for the prosecution in homicide trial in Binghamton, NY
- May 2016 Visited senior forensic science classes at Vestal High School – lectured on forensic anthropology and had practical hands-on learning stations
- April 2016 Hosted senior honors biology class from Binghamton High School – for forensic anthropology lecture and practical hands-on learning stations
- March 2016 Expert witness for the prosecution in front of a grand jury, Binghamton, NY
- Oct 2015 Answered question, “Why don’t grown-up teeth grow back in?” for “Ask a Scientist” column, *Press and Sun Bulletin*, Binghamton, NY, 10.25.15
- April 2015 Hosted senior honors biology class from Binghamton High School – lectured on forensic anthropology and had practical hands-on learning stations
- Nov 2013 Answered question, “How many bones in the human body?” for “Ask a Scientist” column, *Press and Sun Bulletin*, Binghamton, NY, 11.24.13
- Nov 2013 Hosted senior honors biology class from Binghamton High School – lectured on forensic anthropology and had practical hands-on learning stations

## Publications

### Edited Volume

**DiGangi EA** and MK Moore, editors. 2013. Research Methods in Human Skeletal Biology. San Diego: Academic Press.

### Refereed Journal Articles

Moore, MK, **DiGangi, EA**, Niño Ruíz, FP, Hidalgo Davila, OJ, and Sanabria Medina C. 2016. Metric Sex Estimation from the Postcranial Skeleton for the Colombian Population. *Forensic Science International*. DOI: 10.1016/j.forsciint.2016.02.018

**DiGangi, EA** and JE Sirianni. Maxillary Sinus Infection in a 19<sup>th</sup> Century Almshouse Skeletal Sample. 2016. *International Journal of Osteoarchaeology*. DOI: 10.1002/oa.2526

Wilson RJ, Bethard JD, and **EA DiGangi**. 2011. The Use of Orthopedic Surgical Devices for Forensic Identification. *Journal of Forensic Sciences* 56(2): 460-469.

**DiGangi EA**, Bethard JD, and LP Sullivan. 2010. Differential Diagnosis of Cartilaginous Dysplasia and Probable Osgood-Schlatter's Disease in a Mississippian Individual from East Tennessee. *International Journal of Osteoarchaeology* 20(4): 424-442.

**DiGangi EA**, Bethard JD, Kimmerle EH, and LW Konigsberg. 2009. A New Method for Estimating Age-at-Death From the First Rib. *American Journal of Physical Anthropology*. 138(2): 164-176.

### Book Chapters

**DiGangi, EA**. 2016. Scientific Research and Publishing in Biological and Forensic Anthropology. Book chapter for *Antropología y Patología Forense de la Muerte: La Investigación científica y judicial de la muerte y la tortura, desde las fosas clandestinas hasta la audiencia pública*. Translation: "Forensic Anthropology and Pathology of Death: Scientific Research of Death and Torture, from Clandestine Graves Until Trial." Edited by Cesar Sanabria. Bogotá, Colombia: Forensic Publisher.

Bethard, JD, **DiGangi, EA**, and LP Sullivan. Distinguishing impairment from disability in the bioarchaeological record: An example from DeArmond Mound (40RE12) in east Tennessee. In *Embodying Impairment: Towards a Bioarchaeology of Disability* edited by Jennifer F. Byrnes and Jennifer L. Muller. Springer. **In review**.

**DiGangi, EA**. 2013. Library Research, Presenting, and Publishing in *Research Methods in Human Skeletal Biology*. EA DiGangi and MK Moore, eds. San Diego: Academic Press, pp. 483-506.

**DiGangi, EA** and JT Hefner. 2013. Ancestry Estimation in *Research Methods in Human Skeletal Biology*. EA DiGangi and MK Moore, eds. San Diego: Academic Press, pp. 117-150.

**DiGangi, EA** and MK Moore. 2013. Introduction to Research in Human Skeletal Biology in *Research Methods in Human Skeletal Biology*. EA DiGangi and MK Moore, eds. San Diego: Academic Press, pp. 3-28.

**DiGangi, EA** and MK Moore. 2013. Application of the Scientific Method to Skeletal Biology in *Research Methods in Human Skeletal Biology*. EA DiGangi and MK Moore, eds. San Diego: Academic Press, pp. 29-62.

**DiGangi, EA** and MK Moore. 2013. Future Research Considerations in Human Skeletal Biology in *Research Methods in Human Skeletal Biology*. EA DiGangi and MK Moore, eds. San Diego: Academic Press, pp. 507-512.

### **Book Review**

**DiGangi EA**. 2013. Book review of: Photographic Regional Atlas of Bone Disease: A Guide to Pathologic and Normal Human Variation of the Human Skeleton, 3<sup>rd</sup> Edition. *American Journal of Physical Anthropology*. 154(1):168-169.

### **Manuscripts In Preparation**

Sincerbox, SN and **EA DiGangi**. Ecological Influences on Vertebrate Scavenging Behavior and Implications for Forensic Investigation. Book proposal accepted by Elsevier, Academic Press.

**DiGangi EA** and AH McKeown. Skeletal Remains of British Soldiers Garrisoned at Brimstone Hill Fortress, St. Kitts, West Indies, 1690-1853. Being prepared for *Postmedieval Archaeology*.

McKeown AH, **DiGangi, EA**, and TM Ahlman. If the Rum Don't Kill Me, I'll Live Until I Die: A Bioarchaeological Study of British Soldiers from St. Kitts, West Indies. Being prepared for *Postmedieval Archaeology*.

Hammerl, EH, Moore, MK, **DiGangi, EA**, LeReverend, B, and HM Justus. Subadult Mandibular Morphology and Estimated Bite Force of an Early Medieval Skeletal Sample from Northern France Compared with Modern Individuals of European Ancestry. Being prepared for *International Journal of Paleopathology*.

## ***Curriculum Vitae: David Andrew Merriwether***

Current Address 104 Rockwell Rd, Vestal, NY 13850,  
Office: 217 Science I Bldg Office Phone: 607-777-3309  
Lab: 215 Science IV Bldg. Lab Phone: 607-777-6707, Email: [Andym@bingamton.edu](mailto:Andym@bingamton.edu)

### ***Degrees Awarded:***

*B.A.* Medical Anthropology, Pennsylvania State University, May 1988  
*B.S.* Biology (Genetics Option), Pennsylvania State University, May 1988  
*M.S.* Genetics, Pennsylvania State University, December 1989  
*Ph.D.* Human Genetics, University of Pittsburgh, August 1993

### ***Employment Experience:***

Binghamton University (SUNY), Binghamton, NY  
Associate Professor of Anthropology. 6/02-present  
Associate Professor of Biology. 8/05-present.  
Director of Graduate Studies, Department of Anthropology, 8/08-6/15  
Department Chair, Department of Anthropology, 7/15-present  
University of Michigan, Ann Arbor, Michigan  
Assistant Professor of Anthropology, Tenure Track. 9/96-2002  
Assistant Professor of Biology, 12/96-2002  
Faculty Member, Genome Training Grant at U. Michigan, 9/97-2002  
Executive Committee, Genome Training Grant at U. of Michigan, 11/97-2002  
Faculty Member, Institute of Statistical Genetics 9/99-2002  
Faculty member, MAC-EPID Program 11/99-2002  
Faculty Mentor, Michigan Initiative for Women's health Program, University of Michigan, Ann Arbor Michigan, 48109.  
Ohio State University, Columbus, Ohio  
Adjunct Assistant Professor of Anthropology (Courtesy Appointment) 4/97-2003  
W.M. Keck Foundation for Advanced Training in Computational Biology, University of Pittsburgh, Carnegie Mellon University, and the Pittsburgh Supercomputing Center.  
Keck Postdoctoral Fellow, 9/93-9/96  
University of Pittsburgh, Pittsburgh, PA  
Research Associate: Dr. Robert Ferrell Lab, University of Pittsburgh  
Keck Postdoctoral Fellow, W.M. Keck Foundation for Advanced Training in Computational Biology, University of Pittsburgh, Carnegie Mellon University, and the Pittsburgh Supercomputing Center.  
Graduate Student Research Assistant: Dr. Robert Ferrell Lab: University of Pittsburgh, Pittsburgh, PA.  
Emory University, Atlanta, GA  
Research Associate: Dr. Douglas Wallace Lab: Emory University, Atlanta, Ga.

Pennsylvania State University, University Park PA

Teaching Assistant: Biology 101 Lab Instructor: Pennsylvania State University, University Park, Pa.

Lab Assistant: Dr. Andrew G. Clark lab, Pennsylvania State University, University Park, Pa.

***Submitted Manuscripts in Review:***

Shamoon-Pour, M., Fehren-Schmitz, L., Merriwether, DA and Reid, BA (2017 in press) Chapter 7. Mitochondrial HVS-1 Sequences of Pre-Contact Human Remains from the Red House Site. in *AN ARCHAEOLOGICAL STUDY OF THE RED HOUSE IN PORT OF SPAIN (TRINIDAD)*, Edited by REID, BA. Trinidad.

Diaz-Lameiro, AM, Isbell, WH, Stahl, PW and Merriwether, DA (submitted 2016) Guanaco versus Vicuña: Uncovering the Wild Ancestor of the Domestic South American Camelids using Pre-Colombian Ancient DNA. *Heredity*

Diaz-Lameiro, AM and Merriwether, DA (submitted 2016) Domestication of South American camelids clarified using whole mitochondrial genomes. *Molecular Ecology*.

Fehren-Schmitz, L., Merriwether, DA, Shamoon-Pour, M and Reid, B.A. (2017) Chapter 8: DNA Analysis of Human Skeletons found at the Red House.

***Manuscripts in Preparation:***

Bongermine Rose, M, DiGangi, E, Merriwether, DA (in prep). The effects of X-rays on DNA recovery from teeth and bones

Diaz-Lamiero, AM, and Merriwether, DA (in prep) Ancient DNA Suggests Single Domestication Origin for South American Camelids in the Northern Andes. Formatted for *Animal Genetics*.

Lee EJ, Merriwether DA. (in prep) Genetic histories of an indigenous population from southern Venezuela inferred from the mtDNA, Y-STRs, and autosomal STRs.

Kennedy, JL, Diaz-Lamiero, AM, and Merriwether, DA (in prep) The role of the Melanocortin 1 Receptor in alpaca fleece coloration.

Kennedy, JGL, Kuhne, H., and Merriwether, DA. (in prep) "Mitochondrial D-loop characterization of the Roman/Parthian Period cemetery at Tall Šēḥ Ḥamad, Syria"

Kennedy, JGL, Shamoon Pour, M, Pipes, ML, and Merriwether, DA. (in prep) "The Bronocice Sheep Project: The use of ancient mitochondrial DNA analysis of sheep to infer human social interactions during the middle Neolithic in southeastern Poland"

***Peer Reviewed Publications:***



Skoglund, P, Spriggs, M, Sirak, K, Rohland, N, Mallick, S, Valentin, F, Bedford, S, Fernandes, D, Harney, E, Lipson, M, Novak, M, Stewardson, K, Abdullah, S, Cox, MP, Friedlaender, FR, Friedlaender, JS, Kivisild, T, Koki, G, Kusuma, P, Merriwether, DA, Ricaut, F-X, Wee, JTS, Patterson, N, Pinhasi, R, and Reich, D (submitted 2016) Genomic insights into the peopling of the Southwest Pacific. *Nature*. doi:10.1038/nature19844

Lazaridis, I, Nadel, D, Rollefson, G, Merrett, DC, Rohland, N, Mallick, S, Fernandes, D, Novak, M, Gamarra, B, Sirak, K, Connell, S, Stewardson, K, Harney, E, Fu, Q, Gonzalez-Fortes, G, Roodenberg, SA, Lengyel, G, Bocquentine, F, Gasparian, B, Monge, JM, Gregg, M, Vered, E, Mizrahi, A-S, Meiklejohn, C, Gerritsen, F, Bejenaru, L, Blüher, M, Campbell, A, Cavalleri, G, Comas, D, Froguel, P, Gilbert, E, Kerr, SM, Kovacs, P, Krause, J, McGettigan, D, Merrigan, M, Merriwether, DA, O'Reilly, S, Richards, MB, Semino, O, Shamoon-Pour, M, Stefanescu, G, Stumvoll, M, Tönjes, A, Torroni, A, Wilson, JF, Yengo, L, Zalloua, P, Hovhannisyan, NA, Patterson, N, Pinhasi, R, and Reich, D (2016) The genetic structure of the world's first farmers. *Nature*. 2016 Aug 25;536(7617):419-24.

Lee EJ, Merriwether DA, Kasparov AK, Khartanovich VI, Nikolskiy PA, Shidlovskiy FK, Timoshin VB, Pavlova EY, Pitulko VV. (in press 2016) A genetic perspective of prehistoric hunter-gatherers in the Siberian Arctic: ancient DNA analysis of human remains from 8,000 years ago. *Journal of Archaeological Science: Reports*.

Vernot B, Tucci S, Kelso J, Schraiber JG, Wolf AB, Gittelman RM, Dannemann M, Grote S, McCoy RC, Norton H, Scheinfeldt LB, Merriwether DA, Koki G, Friedlaender JS, Wakefield J9, Pääbo S, Akey JM. (2016) Excavating Neandertal and Denisovan DNA from the genomes of Melanesian individuals. *Science*. 2016 Apr 8;352(6282):235-9. doi: 10.1126/science.aad9416. Epub 2016 Mar 17.

Lee EJ, Merriwether DA (2015) Identification of Whole Mitochondrial Genomes from Venezuela and Implications on Regional Phylogenies in South America. *Hum Biol*. 2015 Jan;87(1):29-38.

Lee, E. J., Merriwether, D. A., Kasparov, A. K., Nikolskiy, P. A., Sotnikova, M. V., Pavlova, E. Y., & Pitulko, V. V. (2015). Ancient DNA Analysis of the Oldest Canid Species from the Siberian Arctic and Genetic Contribution to the Domestic Dog. *PLoS ONE*, 10(5), e0125759. <http://doi.org/10.1371/journal.pone.0125759>.

Avila F, Baily MP, Merriwether DA, Trifonov VA, Rubes J, Kutzler MA, Chowdhary R, Janečka J, Raudsepp T. (2015) A cytogenetic and comparative map of camelid chromosome 36 and the minute in alpacas. *Chromosome Res*. 2015 Jan 30. PMID: 25634498.

Avila F, Baily MP, Perelman P, Das PJ, Pontius J, Chowdhary R, Owens E, Johnson WE, Merriwether DA, Raudsepp T. (2014) A Comprehensive Whole-Genome Integrated Cytogenetic Map for the Alpaca (*Lama pacos*). *Cytogenet Genome Res*. 2014;144(3):196-207. doi: 10.1159/000370329. Epub 2015 Feb 6. PMID:25662411.

Duggan AT, Evans B, Friedlaender FR, Friedlaender JS, Koki G, Merriwether DA, Kayser M, Stoneking M. (2014) Maternal history of Oceania from complete mtDNA genomes: contrasting ancient diversity with recent homogenization due to the Austronesian expansion. *Am J Hum Genet.* 2014 May 1;94(5):721-33. doi: 10.1016/j.ajhg.2014.03.014. Epub 2014 Apr 10. PMID: 24726474.

Byrnes J, Merriwether DA, Sirianni JE, Lee EJ (2012). MtDNA and osteological analyses of an unknown historical cemetery from upstate New York. *Archaeological and Anthropological Sciences* 4(4):303-311.

Just RS, Loreille OM, Molto JE, Merriwether DA, Woodward SR, Matheson C, Creed J, McGrath SE, Sturk-Andreaggi K, Coble MD, Irwin JA, Ruffman A, Parr RL. (2011) Titanic's unknown child: the critical role of the mitochondrial DNA coding region in a re-identification effort. *Forensic Sci Int Genet.* Jun;5(3):231-5.

Lee EJ, Koki G, Merriwether DA. (2010) Characterization of population structure from the mitochondrial DNA vis-à-vis language and geography in Papua New Guinea. *Am J Phys Anthropol.* Aug;142(4):613-24.

Lee EJ, Luedtke JG, Allison JA, Arber CE, Merriwether DA, Steadman DW. (2010) The effects of different maceration techniques on nuclear DNA amplification using human bone. *Journal of Forensic Sciences, J Forensic Sci.* 2010 Jul;55(4):1032-8.

Lee EJ, Anderson LM, Dale V, Merriwether DA. (2009). MtDNA origins of an enslaved labor force from the 18<sup>th</sup> century Schuyler Flatts Burial Ground in colonial Albany, NY: Africans, Native Americans, and Malagasy? *Journal of Archaeological Science* 36(12): 2805-2810.

Friedlaender JS, Friedlaender FR, Reed FA, Kidd KK, Kidd JR, Chambers GK, Lea RA, Loo JH, Koki G, Hodgson JA, Merriwether DA, Weber JL. (2008) The genetic structure of Pacific Islanders. *PLoS Genet.* 2008 Jan;4(1):e19.

Hunley, KL, Spencer, J, and Merriwether DA (2008) The Impact of Group Fissions on Genetic Structure in Native South America and Implications for Human Evolution. *American Journal of Physical Anthropology* 135(2):195-205.

Friedlaender, JS, Friedlaender, FR, Hodgson, JA, Stoltz, M, Koki, G, Horvat, G, Zhadanov, S, Schurr, TG, and Merriwether, DA (2007) Melanesian mtDNA complexity *PLoS ONE* 2(2): e248. doi:10.1371/journal.pone.0000248.

Hunley KL, Cabana GS, Merriwether DA, Long JC. (2007) A formal test of linguistic and genetic coevolution in native Central and South America. *Am J Phys Anthropol.* Jan 4; [Epub ahead of print].

Sans M, Merriwether DA, Hidalgo PC, Bentancor N, Weimer TA, Franco MH, Alvarez I, Kemp BM, Salzano FM. (2006) Population structure and admixture in Cerro Largo, Uruguay,

based on blood markers and mitochondrial DNA polymorphisms. *Am J Hum Biol.* Jul-Aug;18(4):513-24.

Cabana GS, Merriwether DA, Hunley K, Demarchi DA., (2006) Is the genetic structure of Gran Chaco populations unique? Interregional perspectives on native South American mitochondrial DNA Variation. *Am J Phys Anthropol.* 2006 Feb 16; [Epub ahead of print] PMID: 16485304.

Lansing, J.S., A.J. Redd, T.M. Karafet, J. Watkins, I.W. Ardika, S.P.K. Surata, J.W. Schoenfelder, M. Campbell, D.A. Merriwether, and M.F. Hammer. (2006). Reply [to: Indian traders in Ancient Bali: A Reconsideration of the Evidence]. *Antiquity* 80(307): online at

Norton HL, Friedlaender JS, Merriwether DA, Koki G, Mgone CS, Shriver MD., (2005) Skin and hair pigmentation variation in Island Melanesia. *Am J Phys Anthropol.* 130(2):254-268.

Cerchio, S, Jacobsen, JK, Cholewiak, DM, Falcone, EA. and Merriwether, DA. (2005) Paternity in humpback whales, *Megaptera novaeangliae*: assessing polygyny and skew in male reproductive success (2005) *Animal Behaviour* Volume 70, Issue 2, 1 August 2005, Pages 267-277.

Allaby RG, Peterson GW, Merriwether DA, Fu YB., (2005) Evidence of the domestication history of flax (*Linum usitatissimum* L.) from genetic diversity of the *sad2* locus. *Theor Appl Genet.* 112(1):58-65.

Merriwether DA, Hodgson JA, Friedlaender FR, Allaby R, Cerchio S, Koki G, Friedlaender JS., (2005) Ancient mitochondrial M haplogroups identified in the Southwest Pacific. *Proc Natl Acad Sci U S A.* 2005 Sep 13;102(37):13034-9.: *Proc Natl Acad Sci U S A.* 2005 Nov 15;102(46)16904.

Friedlaender J, Schurr T, Gentz F, Koki G, Friedlaender F, Horvat G, Babb P, Cerchio S, Kaestle F, Schanfield M, Deka R, Yanagihara R, Merriwether DA., (2005) Expanding Southwest Pacific mitochondrial haplogroups P and Q. *Mol Biol Evol.* 22(6):1506-17.

Lansing, J.S., A.J. Redd, T.M. Karafet, J. Watkins, I.W. Ardika, S.P.K. Surata, J.W. Schoenfelder, M. Campbell, D.A. Merriwether, and M.F. Hammer. (2004) An Indian Trader in Ancient Bali? *Antiquity* 78:300: 287-293.

Robledo R, Scheinfeldt L, Merriwether DA, Thompson F, Friedlaender J., (2003) A 9.1-kb insertion/deletion polymorphism suggests a common pattern of genetic diversity in Island Melanesia. *Hum Biol.* 75(6):941-9.

Mitani, JC, Watts, DP, Pepper, JW and Merriwether, DA (2002) Demographic and social constraints on male chimpanzee behaviour . *Animal Behaviour*, 2002, 64: 727–737.

Friedlaender JS, Gentz F, Green K, Merriwether DA., (2002) A cautionary tale on ancient migration detection: mitochondrial DNA variation in Santa Cruz Islands, Solomon Islands. *Hum Biol.* 2002 Jun;74(3):453-71.

Merriwether, D.A., (2002) The Peopling of the New World: A Mitochondrial Perspective. in *The First Americans: The Pleistocene Colonization of the New World. Proceedings of The Fourth Wattis Symposium. Wattis Symposium Series in Anthropology, Number 25.* 1999, San Francisco, CA.

O'Foighil, D., Jennings, R., Park, J-K, and Merriwether, D.A. (2001) Phylogenetic Relationships of Mid-Oceanic Ridge and Continental Lineages of *Lasaea* (Mollusca: Bivalvia) in the Northeastern Atlantic. *Marine Ecology Progress Series.*

Merriwether, D.A., (2001) Ancient DNA and Kennewick Man: A Review of Tuross and Koman's Kennewick Man aDNA Report. *Current Research in the Pleistocene.*

Smith, C.W., Heath, E., Merriwether, D.A., and Reed, D.M. (2001) Placing a Face In History: Excavation, Facial Re-Construction and DNA Analysis of Skeletal Remains from La Salle's Vessel, La Belle. *BAR INTERNATIONAL SERIES, Volume 934: Pages 105-112*  
Publisher: TEMPUS REPARATISM.

Mitani, J.C., Merriwether, D.A., and Zhang, C. (2000). Male Affiliation and Kinship in Wild Chimpanzees. *Journal of Animal Behavior.*

Merriwether, D. Andrew, Brian M. Kemp, Douglas E. Crews & James V. Neel, (2000). 'Gene flow and genetic variation in the Yanomama as revealed by mitochondrial DNA', in *America Past, America Present: Genes and Languages in the Americas and Beyond*, ed. C. Renfrew. (Papers in the Prehistory of Languages.) Cambridge: McDonald Institute for Archaeological Research, 89-124.

Merriwether, D.A., Kaestle, R.A., Zemel, B., Koki, G., Mgone, C., Alpers, M., and Friedlaender, J., (2000) Mitochondrial DNA Variation in the Southwest Pacific. Ed. By S.S. Paphia, R. Deka and R. Chakraborty in: *Genomic Diversity: Applications in Human Population Genetics.* Plenum Publishers, NY.

Lu, Y., Nerurkar, V.R., Dashwood, W-M, Woodward, C., Sherimay, A., Shikuma, C., Grandinetti, A., Chang, H., Nguyen, H.T., Nu, Z., Yamamura, Y., Boto, W.O., Merriwether, D.A., Jurata, T., Detels, R., and Yanagihara, R. (1999) Genotype and Allele Frequency of a 32-Base Pair Deletion Mutation in the CCR5 Gene in Various Ethnic Groups: Absence of Mutation among Asians and Pacific Islanders. *International Journal of Infectious Diseases: Summer;3(4):186-91.*

Banks, D., Constantine, G., LaFrance, R.A. & Merriwether, D. A. (1999). Analysis of Pairwise Differences of DNA Sequences. *Journal of Non-Parametric Statistics.* 11:1, 215-232.

**Merriwether, D.A.**, J. Friedlaender, J. Mediavilla, C. Mgone, F. Gentz, and R.E. Ferrell (1999). Mitochondrial DNA variation is an indicator of Austronesian influence in Island Melanesia. *American Journal of Physical Anthropology* 110:243-270.

**Merriwether, D.A.** and Kaestle, F.A. (1999) Mitochondrial Recombination? (Continued). *Science* 285:837.

**Merriwether, D.A.**, (1999) Freezer Anthropology: New Uses for Old Bloods. *Philosophical Transactions of the Royal Society Biological Sciences*: 354: 121-129.

**Merriwether, D. A.**, Huston, S., Iyengar, S., Hamman, R., Norris, J. M., Shetterly, S. M., Kamboh, M. I., & Ferrell, R. E. (1997). Mitochondrial versus nuclear admixture estimates demonstrates a past history of directional mating. *American Journal of Physical Anthropology*, 102: 153-159.

**Merriwether, D.A.**, D.M. Reed, & R.E. Ferrell (1997). mtDNA variation in ancient and contemporary Mayans. In S.L. Whittington & D.M. Reed (Eds.), *Bones of the Ancestors: Recent Studies of Ancient Maya Skeletons* Washington, DC: Smithsonian Institution Press.

Easton, R. D., **Merriwether, D. A.**, Crews, D. E., & Ferrell, R. E. (1996). Mitochondrial DNA Variation in the Yanomami: Evidence for Two Additional New World Founding Lineages. *American Journal of Human Genetics*, 59: 213-225.

**Merriwether, D. A.**, Hall, W., Vahlne, A., & Ferrell, R. E. (1996). mtDNA Variation Indicates Mongolia may have been the source for the Founding Population for the New World. *American Journal of Human Genetics*, 59: 204-212.

**Merriwether, D.A.**, & R.E. Ferrell (1996). The Four Founding Lineage Hypothesis: A Critical Re-evaluation. *Molecular Phylogenetics and Evolution* 5: 241-246.

**Merriwether, D. A.**, F. Rothhammer, and R. E. Ferrell (1995). Distribution of the Four-Founding Lineage Haplotypes in Native Americans Suggests a Single Wave of Migration for the New World. *American Journal of Physical Anthropology* : 98(4) 411-430.

**Merriwether, D.A.**, F. Rothhammer, & R.E. Ferrell (1995). mtDNA D-loop 6-bp deletion found in the Chilean Aymara: not a unique marker for Chibchan speaking Amerindians. *Am J Hum Gen.* 56:812-13.

**Merriwether, D.A.** (1994). mtDNA and the Peopling of the New World. *Mother Tongue*, 23:22-28.

**Merriwether D.A.**, Huston S.L., Bunker C.A., Ferrell R.E. (1994) Origins and dispersal of the mtDNA region V 9-bp deletion and insertion in Nigeria and the Ivory Coast. *Am J Hum Gen* 55:A158.

**Merriwether, D.A.**, F. Rothhammer, & R.E. Ferrell (1994). Genetic Variation in the New World: Ancient Teeth, Bone, and Tissue as Sources of DNA. *Experientia*, 50, 592-601.

**Merriwether, D.A.**, F. Rothhammer, & R.E. Ferrell (1993). Mitochondrial DNA D-Loop Sequence Variation in Native South Americans. *American Journal of Human Genetics*, 53(suppl), 833.

**Merriwether, D. A.**, F. Rothhammer, et al. (1992). Mitochondrial DNA Variation in Ancient and Contemporary Amerindians using the tRNALYS-COII Deletion and Diagnostic Restriction Sites. *American Journal of Human Genetics* 51(4): A13.

**Merriwether, D. Andrew**, Andrew G. Clark, Scott W. Ballinger, Theodore G. Schurr, Himla Soodyall, Trefor Jenkins, Stephen T. Sherry, and Douglas C. Wallace. (1991) The structure of human mitochondrial DNA variation. *Journal of Molecular Evolution* 33: 543-555.

Schurr, T.G., S.W. Ballinger, Y.Y. Gan, J.A. Hodge, **D.A. Merriwether**, D.N. Lawrence, W.C. Knowler, K.M. Weiss, and D.C. Wallace. (1990) Amerindian Mitochondrial DNAs have Rare Asian Mutations at High Frequencies, Suggesting They Derived from Four Primary Maternal Lineages. *American Journal of Human Genetics* 46: 613-623.

Clark, A.G., F.M. Szumski, K.A. Bell, L.E. Keith, S. Houtz, and **D.A. Merriwether**. (1990) Direct and Correlated Responses to Artificial Selection on Lipid and Glycogen Contents in *Drosophila melanogaster*. *Genetical Research* 56: 49-56.

***Shorter communications, letters, notes or briefs in refereed publications:***

**Merriwether, D.A.** and Kaestle, F.A. (1999) Mitochondrial Recombination? (Continued). *Science*, 285:837.

**Merriwether D.A.**, Huston S.L., Bunker C.A., Ferrell, R.E. (1994) Origins and dispersal of the mitochondrial DNA region V 9-bp deletion and insertion in Nigeria and the Ivory Coast. *American Journal of Human Genetics* , 55(3):A158.

**Merriwether, D.A.**, Rothhammer, F., and Ferrell, R.E. (1993). Mitochondrial DNA D-Loop Sequence Variation in Native South Americans. *American Journal of Human Genetics*, 53(suppl),833.

**Merriwether, D.A.**, Rothhammer, F., and Ferrell, R.E. (1992). Mitochondrial DNA Variation in Ancient and Contemporary Amerindians using the tRNALYS-COII Deletion and Diagnostic Restriction Sites. *American Journal of Human Genetics*, 51(4): A13.

**Merriwether, D.A.**, (1989), *Molecular Anthropology*. *Bulletin of the National Association of Student Anthropologists*, Vol. 5, No. 2: 6-8.

***Refereed Book Chapters:***



Hunley, K, Dunn, M, Lindström, E, Reesink, G, Terrill, A, Norton, H, Scheinfeldt, L, Friedlaender, FR, Merriwether, DA, Koki, G, and Friedlaender, JS. (2007) Chapter 9. Inferring Prehistory from Genetic, Linguistic, and Geographic Variation. Population Genetics, Linguistics, and Culture History in the Southwest Pacific, Oxford Scholarship Online Monographs September 2007 , pp. 141-155(15).

Friedlaender, JS. Friedlaender, FR. Hodgson, JA. McGrath, S, Stoltz, M, Koki, G, Schurr, TG, and Merriwether, DA (2007) Chapter 4. Mitochondrial DNA Variation in Northern Island Melanesia Population Genetics, Linguistics, and Culture History in the Southwest Pacific, Oxford Scholarship Online Monographs September 2007 , pp. 61-81(21).

Merriwether, D.A. (2006) Mitochondrial DNA. in The Handbook of the North American Indians, Volume 3: Environment, Origins, and Population: Human Biology, General Editor, Sturtevant, William C. Volume Editor, Ubelaker, Douglas H., Washington, D.C.: Smithsonian Institution, Pages 817-830., ISBN 978-0160775116

Friedlaender, JS, Friedlaender, FR, Hodgson, JA, McGrath, S, Stoltz, M., Koki, G, Schurr, TG, and Merriwether, DA. (2005) Mitochondrial genetic diversity and its determinants in Island Melanesia. Andrew Pawley, Robert Attenborough, Jack Golson and Robin Hide, eds, 2005, Papuan pasts: cultural, linguistic and biological histories of Papuan-speaking peoples, Ch. 23: 693–716.

Friedlaender, JS, Friedlaender, FR, Kaestle, F, Schurr, TG, Koki, G, Schanfield, M, McDonough, JW, Smith, L, Cerchio, S, Mgone, C, and Merriwether, DA. (2005) Mitochondrial genetic diversity and its determinants in Island Melanesia. Andrew Pawley, Robert Attenborough, Jack Golson and Robin Hide, eds, 2005, Papuan pasts: cultural, linguistic and biological histories of Papuan-speaking peoples, Ch. 23: 693–716.

Merriwether, D.A., (2002) The Peopling of the New World: A Mitochondrial Perspective. in "The First Americans: The Pleistocene Colonization of the New World." Proceedings of The Fourth Wattis Symposium. Wattis Symposium Series in Anthropology, Number 25. 1999, San Francisco, CA.

Merriwether, D.A., Kemp, B.M., Crews, D.E., and Neel, J.V. (2000). Gene flow and genetic variation in the Yanomama as revealed by mitochondrial DNA, in America Past, America Present: Genes and Languages in the Americas and Beyond, ed. C. Renfrew. (Papers in the Prehistory of Languages.) Cambridge: McDonald Ins. for Archaeological Research, 89-124.

Merriwether, D.A., Kaestle, R.A., Zemel, B., Koki, G., Mgone, C., Alpers, M., and Friedlaender, J., (2000) Mitochondrial DNA Variation in the Southwest Pacific. Ed. By S.S. Paphia, R. Deka and R. Chakraborty in: Genomic Diversity: Applications in Human Population Genetics. Plenum Publishers, New York. pp153-180.

Merriwether, D.A., Reed, D.M., and Ferrell, R.E. (1997). mtDNA variation in ancient and contemporary Mayans. In S.L. Whittington and D.M. Reed (Eds.), Bones of the Ancestors: Recent Studies of Ancient Maya Skeletons Washington, DC: Smithsonian Institution Press.

***Government, University or Industrial reports (non-refereed):***

**Merriwether, D.A.**, and Cabana, G., (2000) Report on Kennewick Man. Submitted to the department of the Interior 9/15/00.

***Shorter communications, letters, notes or briefs in non-refereed publications:***

**Merriwether DA** (2013) Einige Basisregeln über die Farbvererbung bei Alpakas. Frühlingsschau 2013 des Vereins NeuweltkamelidenSchweiz, Fehraltorf (ZH) hippodrome, Switzerland.

**Merriwether, D.A.**, (2010) The Genetics of Grey Alpacas, Alpacas Magazine.

**Merriwether, D.A.** (2009) Toenails and Teeth: Adaptive Traits in Alpacas, AlpacaStreet.com.

**Merriwether, D.A.** (2008) Tools for Investigating Birth Defects: Atresia ani, AlpacaStreet.com, July 2008.

**Merriwether, D.A.**, (2008) A Breeding Plan for Small Breeders in the US Market, AlpacaStreet.com, August 2008.

**Merriwether, D.A.**, (2008) Research Prior to Purchase: What should you do? AlpacaStreet.com, September, 2008.

**Merriwether, D.A.**, (2008) The Alpaca Genome Project. AlpacaStreet.com, June 2008.

**Merriwether, D.A.**, (2007) How to figure out the recessive color. AlpacaStreet.com, July, 2007.

**Merriwether, D.A.**, (2007) Advice to Breeders When Defects Arise, AlpacaStreet.com, September, 2007.

**Merriwether, D.A.**, (2007) Advice against linebreeding, AlpacaStreet.com, October 2007.

**Merriwether, D.A.**, (2007) Domestication of Camelids, AlpacaStreet.com, November 2007.

**Merriwether, D.A.**, (2007) Report on the First International Workshop on Camelid Genetics, AlpacaStreet.com, January 2008.

**Merriwether, D. A.**, and Merriwether, A. M. (2003) Alpaca Color Genetics. Alpacas Magazine. Summer, 2003, pp164-168.

**Merriwether, D.A.**, (2001) Uses of Ancient DNA in Archaeology. The Grapevine Newsletter: For Cultural Resources Management. 11(5):4-7.

**Merriwether, D.A.**, (2001) Politics and Research in Molecular Anthropology, Science Next Wave.

**Awards and Fellowships**



(DATEs) UCLA School of Molecular Evolution Fellowship (\$800):

1993 Keck Scholar, W.M. Keck Foundation for Advanced Training in Computational Biology

1993 Student Honoree, University of Pittsburgh Honors Convocation

1993 Sigma Xi Honor Society, Inducted full member

1993 Omicron Delta Honor Society, Inducted full member

1988 Hillson Fellowship, Pennsylvania State University

1988 Valuable Service Award, National Association of Student Anthropologists

1986-1988 Penn State University Scholars Program, Pennsylvania State University

1985-1987 Golden Key Honor Society

### **Grants, Research Contracts, Forensic and Museum Cases:**

2015-present National Science Foundation Dissertation Improvement Grant (\$11,831): Doctoral Dissertation Research: Understanding Cultural Influences On Population Structure and History through Genetic Analyses of Assyrians. Award Number: 1455744. Principal Investigator; **D. Andrew Merriwether**. Student: Michel Shamoon Pour. Start Date: May 1, 2015, End Date: December 31, 2016 (Estimated)

2015-Present Wenner Gren Foundation for Anthropological Research (\$20,000). The Genetic History of the Assyrian Population. Investigator; **D. Andrew Merriwether**. Student: Michel Shamoon Pour

2015 Norwegian Forensic Evaluation and Paternity Test of multiple personal items from one individual and two relatives (\$2000) contract awarded to **D. Andrew Merriwether**

2012-Present. El rol del ADN en la herencia de las alpacas, color, raza y defectos congénitos. Universidad Nacional de San Antonio Abad del Cusco. (3 million Nuevo Sols, ~\$1.3 million USD) Awarded to Cusco University: **D. Andrew Merriwether** and C. Walter Bravo PIs.

2012 to 2014 Rock Foundation Contract (\$52,000): Siberian Ancient Canine and Human DNA Project. Contract awarded to **D. Andrew Merriwether**.

2013 to 2014 Government of Trinidad and Tobago Contract (\$8,000): Red House Project. Contract awarded to **D. Andrew Merriwether**

2015 Nunavut Government Grant (\$6000) awarded to **D. Andrew Merriwether**

2016 Bradford County Coroner Contract (\$2000): identification of human remains awarded to **D. Andrew Merriwether**

2014 Bradford County Coroner Contract (\$2000): identification of human remains awarded to **D. Andrew Merriwether**

2012-14 National Science Foundation (\$25,000) Bronicice Sheep Project. PI. Pipes. Transferred

100% of funds to **D. Andrew Merriwether** to execute the Grant

2011-2012 US Park Service. Individual Identification Grant (\$2000) awarded to **D. Andrew Merriwether**

2012-2013 US Park Service. Species Identification Grant (\$2000) awarded to **D. Andrew Merriwether**

2005-2007 Alpaca Research Foundation (\$12,000) Mapping the gene(s) for the Suri Phenotype. PI: **D. Andrew Merriwether**

1999-2002 National Science Foundation (Molecular Evolution of the Yanomama), \$285,000, PI: **D. Andrew Merriwether**

1996-2001 Undergraduate Research Opportunity Program, University of Michigan (Molecular Anthropology), \$3000-6,000 per year. PI: **D. Andrew Merriwether**

2001-2003 Office of the Vice President of Research and the College of Literature, Science and the Arts, University of Michigan (Ancient DNA Banking and Confirmation of Ruthven Museum Native American Remains) PI: John O'Shea, Co-PI: **D. Andrew Merriwether** \$100,000

2000 NSF Dissertation: An Investigation of Prehistoric Population Relationships Using Ancient DNA: The Test Case of Azapa Valley, Northern Chile. NSF Award Number: 9910870. Start Date: January 1, 2000, End Date: December 31, 2000 Awarded: \$12,000.00 PI: **D. Andrew Merriwether**. Student Graciela Cabana.

1996-2000 National Science Foundation (The Peopling of Island Melanesia), \$100,000 PI: **D. Andrew Merriwether**

1999-2000 National Science Foundation Extension \$16,800, PI: **D. Andrew Merriwether**

1998-1999 Wenner -Gren Foundation (Genetics of adaptation to altitude), \$12,000, PI: Cynthia Beall, Co-PI **D. Andrew Merriwether**

1999-2000 Office of the Vice President of Research and the College of Literature, Science and the Arts, University of Michigan (Ancient DNA and Modern Human Origins), -\$150,000, PI: **D. Andrew Merriwether**

1999-2000 Louis B. Leakey Foundation (Molecular Evolution of Chimpanzees from Kibale Forest, Uganda), \$5,550, PI: John Mitani, Co-PI **D. Andrew Merriwether**

### **Professional Memberships Past and Present**

Bald Eagle Archaeology Society, Chapter 24, Society for Pennsylvania Archaeology:  
National Association of Student Anthropologists, Unit of the American Anthropological  
Association

American Anthropology Association

Biological Anthropology Section of the American Anthropological Association

Society for Medical Anthropology

Society for American Archaeology

American Association of Physical Anthropologists

American Society of Human Genetics

Society of Molecular Biology and Evolution Member

Ancient Biomolecules Association

American Association of Anthropological Geneticists

American Association for the Advancement of Science

Human Biology Association

### **Professional Service:**

2001-2005: Associate Editor, American Journal of Physical Anthropology,

2000-2005 Executive Committee Member at Large, Biological Anthropology Section,

American Anthropological Association

2000-2003, Associate Editor, Ancient Biomolecules Journal.

1997-2001: Anthropology Newsletter Contributing Editor, Biological Anthropology  
Section,

American Anthropological Association

1998-2000: American Association of Physical Anthropologists Scientific Program Committee

1988-1990: Contributing Editor, Anthropology Newsletter, National Association of Student  
Anthropologists (NASA) , American Anthropology Association (AAA)

1990-1993: Teaching Award Committee Chair, National Association of Student Anthropologists,  
American Anthropology Association

1991-1993: President, National Association of Student Anthropologists, American  
Anthropological Association

1991-1993: Board of Directors, American Anthropological Association

1991-1993: External Relations Committee, American Anthropological Association

1989-1990: Acting President, National Association of Student Anthropologists, American  
Anthropological Association

1988-1990: Editor, National Association of Student Anthropologists, American Anthropological  
Association

1988-1990: Vice-President, National Association of Student Anthropologists, American Anthropological Association

1987-1990: Chairman, Committee for National Student Meetings, National Association of Student Anthropologists, American Anthropology Association

1986-1988: Liaison, National Association of Student Anthropologists, American Anthropological Association

1986-1988: Undergraduate Member-at-Large, National Association of Student Anthropologists, American Anthropological Association

1986-1987: Chairman, Journal Search Committee, National Association of Student Anthropologists, American Anthropological Association

1985-1987: President, Anthropology Promotion and Enrichment Sodality (APES) : Anthropology club, Penn State, University Park, PA.

1984-1986: Vice-President, Bald Eagle Archaeology Society, Chapter 24, Society for Pennsylvania Archaeology

**Internal Service: University Service:**

1997-present: Executive Committee Member, Genetics Training Grant: University of Michigan.

1997-present: Mentor, Michigan Women in Medical Sciences: University of Michigan.

2000-present: Search Committee for three Statistical Geneticists, Department of Biostatistics, Department of Human Genetics, University of Michigan.

Departmental Service:

1998-present: Research Committee Representative to LSA, Department of Anthropology, University of Michigan.

2000-2001: Representative, Life Sciences Values and Society Program, Department of Anthropology, University of Michigan.

1999-2000: Michigan Life Science Corridor Representative, Department of Anthropology, University of Michigan. -1992 Graduate Student Representative to the Executive Committee, Department of Human Genetics, University of Pittsburgh.

8/08-6/15 Director of Graduate Studies, Department of Anthropology, Binghamton University (SUNY), Binghamton, NY

7/15-present Department Chair, Department of Anthropology, Binghamton University (SUNY), Binghamton, NY

2003-present Served on search committees, or acted as Department Chair on searches, for Sedra Amy Snipes, Christine Reiber, Katherine Wander, Matthew Sanger, Sabina Perrino, Rolf Quam, Elizabeth DiGangi, Erica Bornstein

2015-present: Acted as Department Chair for promotion cases of Ralph Garruto, Rolf Quam, and Elizabeth DiGangi, currently Department Chair for Josh Reno's non-mandated tenure and promotion case (Due September 2016).

**Current Doctoral Students with Merriwether as Chair**

Weyi Guo

Stacy McGrath  
Kay Grennan  
Cassandra Koch  
Ruwansha Galegadara

**Current PhD students with Merriwether on committee (not chair)**

Ada Demleitner  
Katrina Ollesch  
Kate DeRosa  
Emily Dew  
Elizabeth Evangelou  
Amelia Hessey  
Elizabeth Celata  
Mandy Guitar  
Mian Li

**Doctoral Students Graduated with Merriwether as Chair (or co-Chair)**

Keith Hunley (now associate professor with tenure at University of New Mexico)  
Graciela Cabana (now associate professor with tenure at University of Tennessee, Knoxville)  
Esther Lee (currently lecturer at Texas Tech University)  
Jennifer Luedtke Kennedy (currently lecturer at Central Michigan University)  
Alondra Diaz Lamiero  
Michel Shamoon Poor (currently clinical research assistant professor at Binghamton University)

**Doctoral Students Graduated with Merriwether as committee member (but not chair)**

Lisa Mills (currently State Epidemiologist for the State of Ohio)  
John Hawks (currently associate professor with tenure at University of Wisconsin)  
Russel Nelson (currently lecturer, Western Wyoming College)  
Sal Cherchio (currently curator, American Museum of Natural History)  
Sara Kindschuh (currently working at Defense POW/MIA Accounting Agency, Central Identification Laboratory, Nebraska)  
Brian Kemp (currently associate professor, Oklahoma State University)  
Amy Huard (currently lecturer at Nashua Community College, Manchester Community College)  
Jeremy Wilson (currently assistant professor Indiana University-Purdue University Indianapolis)  
Migel Vilar (Currently staff member National Geographic Project)  
Ben Figura (currently Deputy Director of Forensic Investigations and Forensic Anthropologist at Office of Chief Medical Examiner, New York City, NY)  
Giovanna Vidoli (Research Assistant Professor, University of Tennessee, Knoxville)  
Dongya Yang (currently Professor, Simon Fraser University)

**Masters Students Graduated with Merriwether as Chair (or co-Chair)**

Jennifer Luedtke  
Lisa Manerino  
Kalen Casey  
Kristin Saari

Elena Kouneski  
Sasha Pinto  
Kay Grennan  
Stacy McGrath  
Matthew Stoltz  
Dan Lynch  
Alexandra Buck  
Leslie Coss  
Randy David (Biology)  
Michelle Rose Bongermano

### **Post-Doctoral Fellows Trained**

David Reed (Currently Research Scientist, Kellogg Eye Center, University of Michigan)  
Salvatore Cherchio (Currently Research Scientist at the New England Aquarium)  
Robin Allaby (Currently Associate Professor at Warwick College in England)  
Frederika Kaestle (Currently Associate Professor at Indiana University)

### **Masters Students Graduated Committee Member (not chair)**

Nicole Jastremski  
Koneru Sree Naresh (Biomedical Engineering)  
Kito Nzingha  
Paulette Steeves

### **Teaching:**

I have taught the following grad courses since coming to Binghamton University. I have had a 3 course per year load from 2007 to 2015. These are in addition to training 3-8 grad students in both anthropology and biology in the lab in independent study. I also usually train between 6 and 18 undergrads in independent study courses each year.

### **Graduate Courses Taught**

515 Evolution Theory  
572M Molecular Anthropology Lab  
559 Molecular Anthropology Theory  
572F Ancient DNA and Forensics Lab  
572P Phylogenetics and Molecular Evolution

### **Undergraduate Courses Taught**

168 Introduction to Biological Anthropology  
333 Human Genetics (I taught this at the 200, 300 and 400 levels, now permanently anth333)  
485 Ancient DNA and Forensics Lab  
380M Molecular Anthropology Lab  
426 Molecular Anthropology Theory  
240 Medical Anthropology for Pre-Health